

Full Length Research Paper

Prevalence of Cervical Rib in an African Population

^{1*}Kolade-Yunusa HO and Salaam AJ²

¹Department of Radiology, University of Abuja/ University of Abuja Teaching Hospital, Gwagwalada, Abuja, Federal Capital Territory, Nigeria.

²Department of Radiology, Jos University Teaching Hospital, Lamingo Jos, Plateau State, Nigeria.

Received 31 January, 2017; Accepted 17 February, 2017

Cervical rib also known as “Eve’s rib” is a component of the body located in the thoracic outlet and by far the least study by radiologist and clinicians. A cervical rib is an important cause of non-traumatic thoracic outlet neurovascular compression. To determine the prevalence of cervical rib among patients undergoing chest radiograph in Gwagwalada, Nigeria. This was a prospective study involving one thousand five hundred and twenty consecutive technically adequate posterior-anterior chest radiographs of both adults and children (>15 years) evaluated for cervical rib over a period of ten months. This study was carried out among children and adults between the ages of fifteen and seventy years with a mean of 38.8 years \pm 18.5. From the 1520 chest radiographs examined for the presence of cervical rib, the prevalence of cervical rib was 0.7% (a total of 10 positive radiographic evidence of cervical rib). There was more bilateral cervical rib in this study with four cervical ribs recorded between 21 and 40 years. Out of the 950 males chest radiographs examined six chest radiographs had cervical rib with prevalence of 0.6% and of the 570 females chest radiographs investigated four chest radiograph had cervical rib with prevalence of 0.7%. The prevalence of cervical rib in this study was similar to what was obtained in Nigeria but lower with other parts of the world.

Keywords: Prevalence, Cervical rib, Chest radiograph, Abuja.

INTRODUCTION

Cervical rib is a component of the body located in the thoracic outlet and by far the least study by radiologist and clinicians. Cervical rib is an important cause of non-traumatic thoracic outlet neurovascular compression (Ezeofor et al., 2016). The supernumerary rib is often missed and undetected via chest radiograph on the other hand the rib can be detected in symptomatic and non-symptomatic patients. Surgical intervention for neurogenic thoracic outlet syndrome (NTOS) is not always successful as residual rib do exist, therefore, patients who present with recurrent symptoms of NTOS need to be evaluated for remaining or residual first ribs. Operative intervention to remove the remaining or residual first rib in this patient subset is beneficial and

can be performed without significant morbidity (Likes et al., 2014).

Cervical ribs are an important cause of neurovascular compression at the thoracic outlet. Previous studies have shown the prevalence of cervical ribs to be between 0.05 and 3%, depending on the sex and race of the population studied (Ezeofor et al., 2016; Likes et al., 2014; Brewin et al., 2009). The big rib sign and the vertical displacement sign can be used to differentiate the right and left ribs on lateral chest radiographs. The clavicle, the xiphoid process, and the sternal angle may be used as anatomic landmarks for rib counting on computed tomographic scans. For rib counting on lateral chest radiographs, the sternal angle or the 12th rib may be used. Anatomic rib variants include developmental deformities, cervical rib, and short rib (Singh 1973; Ried et al., 2010; Newmark and Cassidy 1986). Treatment of symptomatic patients is quiet possible and often than not multidisciplinary which

*Corresponding Author Email: oluseyiamal200@gmail.com;
Tel: +2348023570645

includes; physical therapy, scalene muscle blockade, and surgical decompression (De Martino et al., 2009; Barkhordarian 2007; Black and Scheuer 1997; Ani et al., 2012).

The cervical rib cannot be confidently diagnosed in young children as the costal process of C7 may not fuse with the C7 vertebrae until the age of ten (Black and Scheuer 1997; Ani et al., 2012; Ebeye and Apare 2014; Palma and Carini 1990). This simply so, because the seventh cervical is an elongation of the transverse process of the seventh cervical vertebrae (Ebeye and Apare 2014; Palma and Carini 1990; Ebite et al., 2007; Kurihara et al., 1999).

There is a paucity of data regarding the burden of cervical rib and its complication in our environment. Therefore, the aim of the study was to determine the prevalence of cervical rib in Gwagwalada, Nigeria.

Study area

The study was carried out at the Radiology department of University of Abuja Teaching Hospital, Gwagwalada, FCT Abuja. University of Abuja Teaching Hospital (UATH) - a center of excellence, located in Abuja which is the fastest developing city in Africa. Abuja receives several visitors from Africa countries and the world.

MATERIALS AND METHODS

This prospective study was carried out on one thousand five hundred and twenty thousand consecutive technically adequate posterior-anterior chest radiographs of patients being investigated for various conditions between June 2015 to march 2016 at the radiology department of University of Abuja teaching hospital. The chest radiographs were viewed by a consultant radiologist using good viewing boxes in a room with low ambient light. Only radiographs showing the root of the neck clearly were recruited those which did otherwise were discarded. Patient's information to include age, sex, presence or absence of cervical rib, side/sides of occurrence and presence or absence of symptoms were all recorded. The following criteria for diagnosing cervical rib were used:

1. The rib must abut the seventh cervical vertebral transverse process, which is seen to project horizontally or caudally from the spine, rather than the transverse process of the first thoracic vertebra which extends diagonally upward from the point of origin
2. It must have no connection with the manubrium sterni, although it may form a synostosis with the first rib thus distinguishing it from a rudimentary first rib.

Data Analysis

Data were analyzed using SPSS 19.0 software. Probability values of <0.05 were considered as statistically significant. Chi-square and student *t*-tests were used for the statistical test.

RESULTS

A total of one thousand five hundred and twenty radiographs were analyzed from patients who underwent chest radiographs in the department of Radiology in the hospital. The mean age of the subjects was 38.8 ± 18.5 years. The highest proportion of subject falls within the age range of 31-40 years accounting for 30.3% of the subjects and the lowest proportion being 61-70 years accounting for 3.3% of the subjects studied. The chest radiographs studied for patients within 21-30 years age group accounted for 21.1% of all the radiographs, therefore the vast majority of patients studied were between 21-50 years age group. (Table 1). There was 950 males chest radiograph (63.0%) and 570 females chest radiograph studied (38.0%) and the male to female ratio (M: F) was 2:1.

From the 1520 chest radiographs examined for the presence of cervical rib, the prevalence of cervical rib in University of Abuja Teaching Hospital Gwagwalada was 0.7% (a total of 10 positive radiographic evidence of cervical rib). Of the 10 chest radiograph, three chest radiograph from the 21 – 30 years age group giving a prevalence rate of 0.9%; Two (20.0%) from the 31-40 years age group with prevalence rate of 0.4%; 2 (20.0%) from the 41-50 years age group with prevalence rate of 0.7%; 1 cervical rib each from the 51-60 years and 61-70 years age groups, giving a prevalence of rate 0.5% and 2% respectively (Table 1). There was predominant bilateral cervical rib in this study with four cervical ribs recorded between 21 and 40 years. Out of the 950 males, chest radiographs examined six chest radiographs had cervical rib with the prevalence of 0.6% and five chest radiographs of the six chest radiographs were bilateral while the remaining one unilateral cervical rib among males chest radiograph was situated on the left side of the chest. Out of the 570 females, chest radiographs investigated four chest radiographs had cervical rib with prevalence of 0.7% and two chest radiographs out of the four chest radiographs were bilateral while the remaining two unilateral cervical ribs among females chest radiograph were situated on the left and right rib cage respectively. This distribution was statistically significant ($p=0.001$, Table 2).

In terms of symptom with respect to the presence of cervical rib, two patients with bilateral cervical ribs presented with pain in the arm, both patients were

Table 1. Age Distribution of Patients with Cervical rib in Gwagwalada.

Age Group (Years)	Freq (Percent)	Cervical Rib (Percent)	Prevalence (%)	Position	
				Bilateral	Unilateral
15 – 20	201 (13.2)	1 (10.0)	0.5	1	0
21 – 30	320 (21.1)	3 (30.0)	0.9	2	1
31 – 40	460 (30.3)	2 (20.0)	0.4	2	0
41 – 50	288 (18.9)	2 (20.0)	0.7	1	1
51 – 60	201 (13.2)	1 (10.0)	0.5	1	0
61 – 70	50 (3.3)	1 (10.0)	2.0	0	1
Total	1520 (100.0)	10 (100.0)	0.7	7	3

Table 2. Sex Distribution of Patients with Cervical rib.

Gender	Freq (Percent)	Cervical Rib (Percent)	Prevalence (%)	Position		
				Bilateral		Unilateral
				Left	Right	
Males	950 (62.0)	6 (60.0)	0.6	5	1	0
Females	570 (38.0)	4 (40.0)	0.7	2	1	1
Total	1520 (100.0)	10 (100.0)	0.7	7	2	1

females and both were between the ages of 51 to 70 years. The remaining five bilateral cervical ribs were obtained as an incidental finding on examination of chest radiograph representing 71.4% of the total bilateral cervical ribs. One patient with unilateral cervical rib aged 48 years presented with pain in the left arm. This association was not statistically significant ($p=0.072$, Table 3).

DISCUSSION

The prevalence of cervical rib among one thousand five hundred and twenty (1520) patients who had chest radiograph at the radiology department in University of Abuja Teaching Hospital was 0.7%. This figure in the current study is similar to investigations in other parts of Nigeria, (Ezeofor et al., 2016; Ani et al., 2012; Ebeye and Apare 2014) but varies with values in other parts of the world (Palma and Carini 1990; Ebite et al., 2007).

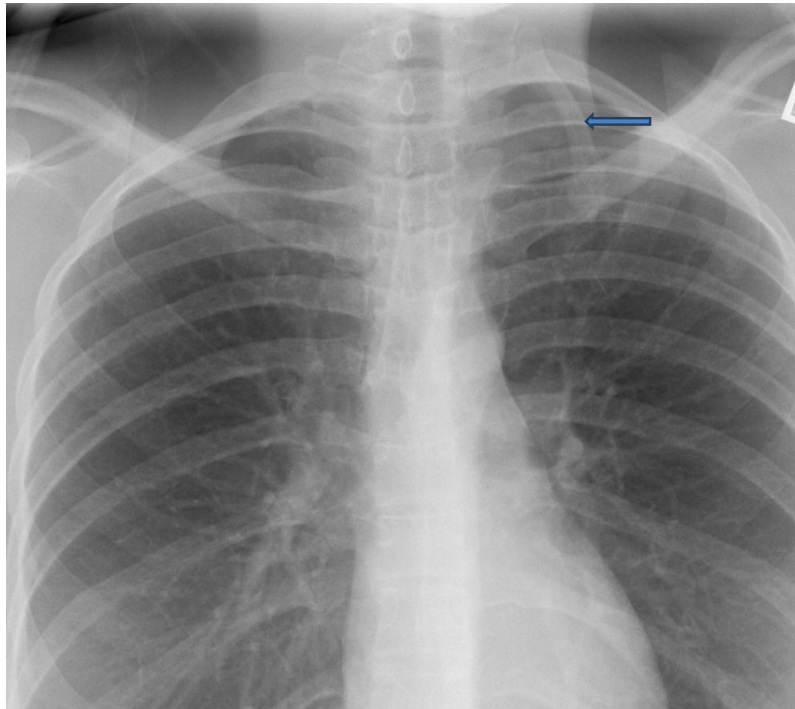
The overall prevalence of 0.7% of cervical rib in this study is higher than 0.6% prevalence from 500 chest radiographs investigated in south-south Nigeria by (Ebeye and Apare 2014), 0.58% prevalence among adults patients reported by (Ebite et al., 2007) among Malawian population, and 0.6% prevalence reported among 12950 chest radiograph reported in Indian (Kurihara et al., 1999) but lower than 2.4% prevalence among 724 patients reported by (Palma and Carini 1990). The differences may be due to the fact that the prevalence of cervical rib varies remarkably among regions of the world as well as among ethnic group (Ezeofor et al., 2016, Ebeye and Apare 2014). This is a

phenomenon that has high genetic variables. In this study, the investigator was meticulous in reading the film and the entire radiograph was cross check. In Nigerian population, the prevalence obtained in this study was the same with the prevalence obtained from 1384 adults patients in north central Nigeria (Ani et al., 2012) and the study reported in Enugu, southeastern Nigeria (Ezeofor et al., 2016), where 6571 chest radiograph were studied. The consistency observed may also be due to the methodology employed and the type of imaging technique used, in all these studies conventional non-digital radiography was used. Using a digital radiography may lead to higher resolution and hence higher chances of detection of cervical rib while conventional non-digital x-ray machine might lead to non-detection of those patients with the less developed cervical rib. Despite using non-digital conventional x-ray, the number of radiographs examined differs. In this study, 1520 radiographs were studied while 500 films were examined in the study from Delta (Ebeye and Apare 2014), south-south, Nigeria.

This study recorded a high number of males than females (950 Vs 570) and the sex-specific prevalence rate was higher in females with prevalence rate of 0.7% while that of males was 0.6%. This was consistent with sex-specific prevalence reported from Jos (Ani et al., 2012), Enugu (Ezeofor et al., 2016) and Delta (Ebeye and Apare 2014). There was predominantly bilateral existence of cervical rib in this study in contrast to the unilateral cervical rib. This is consistent with finding by (Ezeofor et al., 2016) in south-east, Nigeria, where twenty-seven of the total (48) cervical rib observed were bilateral but at variance with some other reports (Ani et

Table 3. Cervical Rib in Patients with Symptoms

Cervical Rib	Symptomatic (Percent)	Incidental (Percent)
Bilateral	2 (66.0)	5 (71.4)
Unilateral		
Right	0 (0.0)	1 (14.3)
Left	1 (30.0)	1 (14.3)

**Figure 1.** Chest radiogram PA view showing left cervical rib

al., 2012; Ebeye and Apare 2014; Ebite et al., 2007). These differences may, however, be due to the type of patients presenting to the health care facilities and not due to chance or the type of machine used.

Patients with cervical rib will either present with symptoms or without symptoms but are usually asymptomatic and are detected when a chest or neck X-ray is taken for some other purposes. Most of the patients studied with cervical ribs were asymptomatic, although this association was not statistically significant. This finding in relation with symptoms is consistent with the well-known knowledge that very few patients present with the symptom. For those that are symptomatic it is usually due to the rib pressing on the nerves or blood vessels as they go from the spinal column to the arm termed the thoracic outlet syndrome. Generally, symptoms are classified into vascular or neurological manifestation. Sensory symptoms like pain and tingling numbness are complained of in the forearm and hand, especially the inner side corresponding to the little finger.

Motor symptoms include weakness of the arm and hand and impaired fine movements like writing and sewing (Ebeye and Apare 2014). If the blood vessels like the subclavian artery are compressed, there may be bluish discoloration of the skin of that limb due to diminished blood supply or in rare cases frank gangrene of the fingers and the pulse at the wrist may be weak or absent. Those who are symptomatic are managed conservatively with the use of analgesics, physiotherapy, muscle relaxants and lifestyle modification. Those with severe symptoms undergo surgery. The patients in this studied who were symptomatic presented with pain and were managed conservatively.

CONCLUSION

The prevalence of cervical rib in Gwagwalada is 0.7% and this is more common among females than males and occurred predominantly as bilateral existence rather

than unilateral. Improved diagnostic apparatus will improve the diagnosis of patients and allows for possible intervention in order to prevent complications.

REFERENCES

- Ani CC, Adegbe EO, Ameadaji M, Gabkwet. A (2012). Cervical Rib Variant in a Nigerian Population. *Jos Journal of Medicine*. Vol 6 No. 1, pp. 60-62
- Barkhordarian S (2007). First rib resection in thoracic outlet syndrome. *J Hand Surg. Am*. Vol. 32 No. 4, pp 565-570.
- Black S, Scheuer L (1997). The Ontogenetic developing of the cervical rib. *Int J Osteoarcheol*. Vol. 7 No. 1, pp.2-10.
- Brewin J, Hill M, Ellis H (2009). The prevalence of cervical ribs in a London population. *Clin. Anat.*; Vol. 22 No.3, pp. 331-336.
- De Martino RR, Stone DH, Beck AW, Walsh DB (2009). Thoracic outlet syndrome associated with a large cervical rib. *Vasc Endovascular Surg*. Vol. 43 No. 4, pp. 393-394.
- Ebeye OA, Apare W (2014). Prevalence of cervical rib in a Nigeria population. *JOSR Journal of Dental and Medical Sciences*. Vol. 13 No. 1, pp. 05-07.
- Ebite LE, Igbigbi PS, Chisi JE (2007). Prevalence of true cervical rib in adult Malawian population. *J. Anat Sci*. Vol. 1 No. 1, pp. 7-9.
- Ezeofor SN, Njeze NR, Aghaji MN, Onuh AC, Obikili EN (2016). The prevalence of cervical ribs in Enugu, Nigeria. *Niger J. Clin. Pract*. Vol. 19 No. 4, pp. 513-516.
- Kurihara Y, Yakushiji YK, Matsumoto J, Ishikawa T, Hirata K (1999). The ribs: anatomic and radiologic considerations. *Radiographics*. Vol. 19 No. 1, pp. 105-119.
- Likes K, Dapash T, Rochlin DH, Freischlag JA (2014). Remaining or residual first ribs are the cause of recurrent thoracic outlet syndrome. *Ann Vasc. Surg.*; Vol. 28 No. 4, pp. 939-945.
- Newmark H, Cassidy TD (1986). Cervical rib diagnosis by computerized tomography. *ComputRadiol* Vol. 10 No. 4, pp. 171-173.
- Palma A, Carini F. (1990) Variation of the transverse apophysis of the 7th cervical vertebrae anatomoradiological study of an isolated population. *Arch Ital Anat Embriol*. Vol. 95 No. 1, pp. 11-16
- Ried M, Diez C, Wiebe K, Hofmann HS (2010). Progredient neurogenic and vascular thoracic outlet syndrome due to bilateral cervical ribs. *Ann Thorac Surg*. Vol. 89 No. 3, pp. 988.
- Singh HK. Incidence of congenital rib anomalies (1973). *Indian J Chest Dis*. Vol. 15 pp 157-164.

How to cite this article: Kolade-Yunusa HO, Salaam AJ (2017). Prevalence of Cervical Rib in an African Population. *Int. Inv. J. Med. Med. Sci*. Vol. 4(1): 1-5