
Contents lists available at [Sjournals](http://Sjournals.com)



Journal homepage: www.Sjournals.com



Original article

Comparative weight assessment of some visceral organs in adult pigeon (*Columba livia*) and Japanese quail (*Coturnix japonica*)

S.A. Hena*, M.L. Sonfada, A. Danmaigoro, A. Bello

Department of Veterinary Anatomy, Faculty of Veterinary Medicine, Usmanu Danfodiyo University, Sokoto, Nigeria

*Corresponding author; Department of Veterinary Anatomy, Faculty of Veterinary Medicine, Usmanu Danfodiyo University, Sokoto, Nigeria; Tel.: +2348060524623

ARTICLE INFO

ABSTRACT

Article history:

Received 03 August 2012

Accepted 26 August 2012

Available online 29 August 2012

Keywords:

Comparative

Weight

Organs

Pigeon

Quail

The work was aimed at comparative assessment of the weights of the heart, liver and lungs in both pigeon and quail and comparison made. In the course of this study twenty birds were used comprising of ten quails and ten pigeons. The mean weights of the heart in the quail and pigeon were 2.38 ± 0.25 g and 2.95 ± 0.22 g respectively, this was not statistically significant ($P > 0.05$). Statistical significant differences ($P < 0.05$) was observed for in the liver of the quail and pigeon with a mean weights of 4.53 ± 0.29 g and 5.96 ± 0.44 g respectively. The lungs from quail and pigeon had their mean weights as 1.83 ± 0.30 g and 3.80 ± 0.52 g respectively, this was considered significant ($P < 0.05$). The knowledge of the weights of these organs may be useful in giving insight into their anatomical and physiological adaptation which consequently could be useful in breeding programmes or as models for feed formulation and nutrient trials. The baseline data will be valuable for further pharmacological and nutritional investigations involving these organs in the two bird types.

© 2012 Sjournals. All rights reserved.

1. Introduction

The Japanese quail is a small avian species kept for meat and egg production (Minvielle, 1998; Baumgartner, 1994). It is widely being used as a model in research in a variety of disciplines including physiology, nutrition, endocrinology, pathology, embryology, reproduction and immunology. Physiological and anatomical parameters serve as valuable tools for predicting outcome consequences (Tilgar et al., 2008; Vatsalya and Arora, 2011).

The pigeon (*Columbia livia*) is one of the commonest birds kept and bred by amateurs as ornamental birds, messenger and for meat purpose and a member of the bird family *Columbidea* (doves and pigeons) (Gibbs et al., 2007). They originally originated from Europe, and at present widely distributed all over the world. During the eighteenth and nineteenth centuries, feral pigeons were spread intentionally and/or accidentally by travelers (Johnston and Janiga, 1995). They are robust, resistant to disease and easy to keep requiring only simple cage and equipment and little space and can be kept on free range. Pigeon production is cheap as the pigeons are mostly kept on free range with only small boxes or houses, which accommodate them and requires less capital outlays in terms of housing, management and health care (Omojola et al 2012; Kigir et al., 2010). Pigeon are raised by many peasant farmers, they are hardly and less susceptible to many diseases of poultry birds. They are gentle and because of their long wings and powerful flight muscles, they are strong, swift flier.

In the field of ornithology oriented on anatomical and ecological investigations, a number of interesting works have been published that refer to the size of body and organs of various species in relation to a range of environmental and physiological parameters. Among these works are the work of Iwaniuk and Nelson, (2001) on brain, the work of Casotti, (2001) on kidneys, the works of Hume and Biebach, (1996) on stomach, a work on heart by Pearson et al., (2000) and the study conducted by Tarhyel et al., (2012) on heart, liver and testes in Japanese quail. There is no evidence of works seen by the authors on the comparative weight assessment of Japanese quails and pigeon, and thus the need to bridge the gap. The knowledge of the weights of these organs may be useful in giving insight into their anatomical and physiological adaptation which consequently could be useful in breeding programmes or as models for feed formulation and nutrient trials.

2. Material and methods

Twenty birds (ten pigeons and ten Japanese quails) of both sexes were purchased from poultry market in Sokoto metropolis, Sokoto state, Nigeria. Immediately after purchase, the birds were caged in well ventilated cages and transported by road to the Department of Veterinary Anatomy, Faculty of Veterinary Medicine, Usmanu Danfodiyo University, Sokoto. The birds were sedated lightly using chloroform as inhalant anaesthetic. The body weight (live weight) of each bird was obtained with a Digital Electronic balance (CITIZEN SCALES 1 PVT. LTD Model MP- 600, with a sensitivity of 0.01g). The birds were then euthanized by an overdose of chloroform soaked on cotton wool and the birds put in an enclosed container. With the birds on dorsal recumbency an incision was made caudo-cranially from the vent to the shoulder joint on the lateral surface, the keel bone and associated muscles were reflected to the opposite thereby giving access to the viscera. The location of the heart, liver and lungs were studied in-situ, and then the organs were snapped using a digital camera (Model ES10, 8.1 MEGA PIXELS) exteriorized and their individual weights obtained using the sensitive Digital Electronic balance. The data generated were subjected statistical analyses using the Microsoft Office Excel 2007 and GraphPad Instat statistical package, with values of $P < 0.05$ considered significant.

3. Results and discussion

Table 1 below shows a summary of the mean weights of the heart, liver and lungs as well as the body weight of the Japanese quail, while Table 2 recorded the summary of the mean weights of the heart, liver and lungs as well as the body weight of the Pigeon. Plates 1 and 2 shows the visceral organs of quail and pigeon in-situ.

From both bird types the heart was found to be located in the thoracic cavity in close relation to the lungs and trachea and cranial to the liver (Plate 2). The heart is similar in shape and construction to the mammalian heart (Sakas, 2002). Like the mammalian heart, the hearts in these birds had four chambers - a right atrium and ventricle which receives deoxygenated blood from the body and sends it to the lungs and a left atrium and ventricle which receives oxygenated blood from the lungs and sends it to the body. In this study the mean weight of the heart in the quail was 2.38 ± 0.25 g with a percentage relative weight of 1.48%, the pigeon had a mean weight

of the heart as 2.95 ± 0.22 g and a percentage relative weight of 1.08 %. The weight of the heart in these birds though apparently different from each other but statistically there is no significant difference ($P > 0.05$).

The size of the heart in relation to body mass was found to be larger in these birds, this agreed with the finding as reported by an Anonymous source (2012). This may relate to the high demand to meet the physiological activities of the birds. Birds have a much higher metabolic rate than mammals. The average body temperature of a avian is 41-45 degrees Celcius, compared to mammals which has relatively lower body temperature. The pulse rate of birds can reach as high as 400 beats/min (Anonymous, 2012). All of these factors place a great demand on the bird's heart which has to work much harder than a mammalian heart. The bird's heart is adapted to handle the increased stress placed on it by its high metabolic rate.

Table 1

Mean organ weight of Quail (\pm SEM), n =10

Parameter	Minimum		Average Value (\pm SEM)	Relative Weight (%)
	Value	Maximum Value		
Heart (g)	1.4	4.0	2.38 ± 0.25	1.48
Liver (g)	3.1	6.1	4.53 ± 0.29	2.82
Lungs (g)	1.0	4.0	1.83 ± 0.30	1.14
Body weight (g)	135.5	202.3	160.57 ± 7.79	100

Table 2

Mean organ weights of Pigeon (\pm SEM) n=10.

Parameter	Minimum		Average Value (\pm SEM)	Relative Weight (%)
	Value	Maximum Value		
Heart (g)	1.8	4.2	2.95 ± 0.22	1.08
Liver (g)	3.0	7.0	5.96 ± 0.44	2.20
Lungs (g)	0.9	6.8	3.80 ± 0.52	1.40
Body weight (g)	240.2	285.0	270.88 ± 4.08	100

In this study the lungs of both quail and pigeon are both found to be bright red in color and impregnated within the rib cage with a contact on its dorsal surface by the thoracic vertebrae in such a way that they delineate vertebral impression on the lung surfaces. The weight of the lungs (both right and left lobes) for quail and the pigeon were found to be 1.83 ± 0.30 g and 3.80 ± 0.52 g respectively. The percentage relative weights for the quail and the pigeon were 1.14% and 1.40% respectively. This was found to be very significant statistically ($P < 0.05$), this implies that in relative terms the pigeon have larger lungs than the quail. This finding may relate to the fact that pigeons are higher and longer fliers compared to the quail.

The lung is a relatively rigid structure that does not expand and retract with breathing; its function is to provide a large surface area for gas exchange with the blood and it does this in a very small space. The lungs are compactly fit against dorsal wall of thorax and they do not expand or contract (Sakas, 2002). The general functions of the lungs are to provide for the exchange of gases, filtering of blood, and storage of blood from the right side of the heart before entering into systemic circulation. The lungs of birds are relatively small, but are connected to 8-9 air sacs that extend through much of the body, and are in turn connected to air spaces within the bones. Though birds have smaller lungs per unit body mass than mammals by a factor of 27% (Maina et al. 1989), the rigidity of the avian lung has permitted substantial increase in the respiratory surface area by intense internal subdivision.

The liver of both Pigeon and Quail was found to be smooth, chocolate in color and glossy in appearance. It is a bilobed organ found situated in the part of the thoraco-abdominal cavity in close association with the

proventriculus and spleen and caudal to the heart (Plates 1 and 2). The right lobe of the liver is relatively larger than the left lobe in both bird types and the gall bladder is found to lie on the right lobe beneath the spleen in the quail. The liver of the quail in this study had a mean weight of $4.53 \pm 0.29\text{g}$ constituting 2.82% of the total body weight, while that of the Pigeon had a mean weight of $5.96 \pm 0.44\text{g}$ with a constituent total body weight of 2.20%. This variation then implied that the weight of the liver in the quail is relatively higher than that of the pigeon and this was also found to be statistically significant ($P < 0.05$), though the body weight (live weight) of the pigeon was found to much higher and statistically extremely significant to that of the quail ($P < 0.05$).

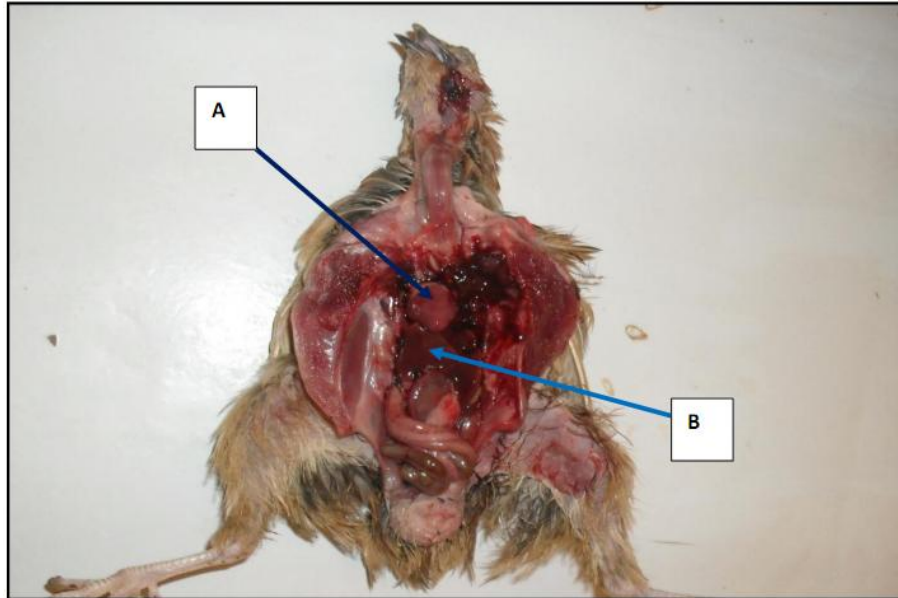


Plate 1. Visceral organs of a Quail in-situ: Showing the Heart (A-arrow) and the Liver (B-arrow).

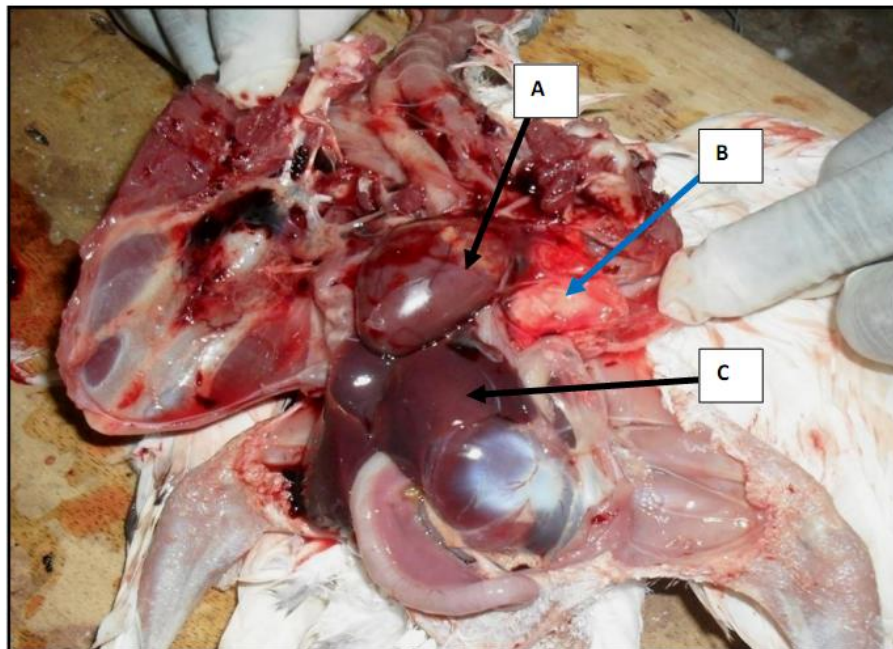


Plate 2. Visceral organs of Pigeon in-situ: Showing the Heart (A-arrow), Lungs (B-arrow) and Liver (C-arrow).

The weight of the liver in pigeon was found to closely rhyme with the findings of Pauline et al., (1997) where they found the weight of an adult pigeon liver to be 5.59g, the liver can normally be quite large. In the work of El-

Shafey et al., (2008) they reported the weight of the liver in pigeon to represent 3.2% of the total body weight. This had been found contrary to the findings in this present research in which the liver weight represented 1.40% of the total body weight.

In their works on quail, Tarhyel *et al.*, (2012) reported increased in the weights of liver with age advancement from juvenile to adult stage of Japanese quail, with a value of 3.02 ± 0.16 g at 52 week old bird, though in this present study we only used adult birds without the inclusion of younger ones. Similarly, Banerjee, (2010) reported weight values of 2.19 ± 0.25 g for the liver of adult male quail with a body weight of 216.66 ± 5.58 g and 5.95 ± 0.40 g as the liver weight for the female counterpart which had a mean body weight of 251.08 ± 6.65 g. In this present study however, sexual dimorphism was not taken into consideration since our work was centered on the study on some organs common to both sexes.

The liver plays a crucial role in the defense against disease and often a bird that is ill will have an enlarged liver, elevated liver enzymes and icteric serum. Perhaps the significant direct involvement that the liver plays in avian disease is due to the fact that birds do not possess definite lymph nodes, rather they possess patches of lymphoid tissue, so that the role of the liver is enhanced. Various anatomical and physiological parameters are regularly being used in clinical evaluations from birth to adult age. Anatomy and physiology are intertwined and various physiological characteristics, undoubtedly, reflect on the capability performance of anatomical structures in health and in disease.

4. Conclusion

Conclusively, this study furnished information on the weights of the heart, liver and lungs in both Japanese quail and the pigeon from the study area. The baseline data will be valuable for further pharmacological and nutritional investigations involving these organs in the two bird types.

References

- Anonymous, 2012. Avian anatomy.
www.chickscope.beckman.uiuc.edu/explore/embryology/day02/comparativehtml
- Banerjee, S., 2010. Carcass study of Japanese quail (*Coturnix coturnix japonica*) reared in hot and humid climate of Eastern India. *World App. Sci. J.* 8(2), 174-176.
- Baumgartner, J., 1994. Japanese quail production, breeding and genetics. *World Poultry Sci. J.* 50, 227-235.
- Casotti, G., 2001. Effects of season on kidney morphology in house sparrows. *J. Exp. Biol.* Vol. 204, P. 1201–1206.
- El-Shafey, A.A., El-Shaieb, M.O., Metwally, M.A.M., 2008. Some comparative anatomical studies on the liver in the ducks, chicken and pigeon. In: Abstracts of the 1st congress of the Afr AVA, Cairo, 17-18 Feb. P 91.
- Gibbs, D., Eustace, B., John, C., 2007. Pigeon and Doves. A Guide to the Pigeons and Doves of the World. United Kingdom: Pica Press. pp 624. ISBN 1873403607.
- Hume, I.D, Biebach, H., 1996. Digestive tract function in the long distance migratory garden warbler, *Sylvia borin*. *J. Comp. Physiol.* 166, 388–395.
- Iwaniuk, A.N., Nelson, J.E., 2001. A comparative analysis of relative brain size in waterfowl (Anseriformes). *Brain Behav Evol.* 57, 87–97.
- Johnston, R.F., Janiga, M., 1995. Feral pigeons. Possible Relevance of Pigeons as an Indicator Species for Monitoring Air Pollution. Oxford University Press, New York, New York, USA. P319.
- Kigir, E.S., Sivachelvan, M.N., Kwari, H.D., Sonfada, M.L., Yahaya, A., Thilza, I.B., Wiam I.M., 2010. Gross and Microscopic Changes in the Gonads of Male and Female Domestic Pigeon (*Columbia Livia*). *New York Sci. J.* 3(10), 108-111.
- Maina, J.N., King, A.S., Settle, G., 1989. An allometric study of the pulmonary morphometric parameters in birds, with mammalian comparison. *Phil. Trans. Royal Soc. London B* 326, 1–57.
- Minvielle, F., 1998. Genetic and breeding of Japanese quail for production around the world. Proc 6th Asian Pacific Poultry Congress, Nogaya, Japan. June, 4-7.
- Omojola, A.B., Isa, M.A., Jibir, M., Ajewole, B.T., Garba, S., Kassim, O.R., Omotoso, A. B., Adeyemo, O.A., Akinleye, S.B., 2012. Carcass Characteristics and Meat Attributes of Pigeon (*Columbia Livia*) as Influenced by Strain and Sex. *J. Anim. Sci. Adv.* 2012, 2(5), 475-480.

- Pauline, A.E.L., Schilderman, J. A., Hoogewerff, F.S., Lou, M., Maas, E.J.C., Moonen, B. J.H., Os, J. H., Van, W., Jos, C.S.K., 1997. Environ. Heal. Perspec. 105(3), Pp 322-330.
- Pearson, J.T., Moriya, K., Yanone, M., Tazawa, H., 2000. Development and regulation of heart rate in embryos and hatchlings of gulls (*Larus schistisagus* and *Larus crassirostris*) in relation to growth. J. Comp. Physiol. 170. P. 429–438.
- Sakas, P.S., 2002. Basic Avian Anatomy. In: Essentials of Avian Medicine: A Guide for Practitioners, Second Edition. Published by the American Animal Hospital Association Press.
- Tarhyel, R., Hena, S.A., Tanimomo, B.K., 2012. Effects of age on organ weight and carcass characteristics of Japanese quail (*Coturnix Japonica*). Scient. J. Agri. 1(1), 21-26.
- Tilgar, V., Kilgas, P., Viitak, A., Reynolds, S.J., 2008. The rate of bone mineralization in birds is directly related to alkaline phosphatase activity. Physiol. Biochem. Zool. 81,106-111.
- Vatsalya, V., Arora, K.L., 2011. Association between body weight growth and selected physiological parameters in male Japanese quail (*Coturnix japonica*). Int. J. Poul. Sci. 10, 680-684.