



Full Length Research Paper

## Sub acute toxicity studies of the herbal cough mixture (hamekof) in adult male wister rats

\*Otimenyin SO, \*Olorunfemi PO., Sabo YS and Attah SH

\*Department of Pharmacology, + Department of Pharm. Tech., Faculty of Pharmaceutical Science, University of Jos, Plateau State, Nigeria.

\*Corresponding Author's Email: [sundayotimenyin@gmail.com](mailto:sundayotimenyin@gmail.com)

### ABSTRACT

Sub-acute toxicity study was designed to investigate and ascertain the safety profile of the herbal cough mixture (Hamekof) in adult male wister rats. In this study, Hamekof was administered orally based on the body weight of the rats for a period of 28 days while the control group received 2 mls of distilled water for the same period. There were no changes in behaviors and physiological activities. Blood chemistry analysis showed no significant changes in the plasma concentration of albumin, cholesterol, triglyceride, creatinine, Total protein, potassium, alanine transaminase, (ALT), alkaline phosphatase, (ALP). Hamekof altered blood levels of aspartate transaminase, (AST), calcium, urea and sodium plasma concentration. Haematological analysis showed no significant changes in blood parameters (WBC count, RBC count, PCV, hemoglobin (Hb) concentration, platelet and differential count) except for clotting time, which was significantly reduced. There were no significant difference in the body and organ weights between control and treated animals. Gross and histopathological examination revealed normal cells, with no abnormalities nor histopathological changes.

**Keywords:** Hamekof, sub-acute toxicity, medicinal plants, liver enzymes.

### INTRODUCTION

Hamekof is a medicinal cough preparation sold in Nigerian market for the management of cough. It is produced and distributed by Hameko Naturalist Hospital Ltd. It contains: *Luffa aegyptiaca*; *Tillia species*; *Filipendula ulmaria*; *Allium cepa*; *Verbena officinalis*; *Lycopersicon Esculentum*; *Marrubium vulgare*; *Gamma globulin*; *Lactuca virosa*; and *Eucalyptus Globulus*.

*Luffa aegyptiaca*. Mill, is known as Baska (Hausa), ásśá (Igbo) and kààkan (Yoruba) in Nigeria. *Luffa aegyptiaca* contains luffaculin, a substance that have been reported to have cytotoxic and inhibitory effects on proliferation of the type 1 ribosome - inactivating protein, (Ng, *et al.*, 1992), abortifacient, immunomodulatory and anti- AIDS, (Ng, *et al.*, 1992), and anti-diabetic activity, (El-Fiky, *et al.*, 1996).

*Filipendula Ulmaria*, is commonly known as Meadowsweet, Dollof, or queen of the meadow. It is rich in salicylic acid, favonone – glycoside, essential oil and tannins. Pharmacological evaluation revealed that it contains aspirin, a substance that inhibits platelet

aggregation, reduces pain and inflammation, (Jen-Hsou *et al.*, 1998). It is used locally for the production of wine and beer, for its vinegar flavor, and as an anti-acid and anti-diarrhea agent, (Neltje Blanchan, 2002).

*Allium Cepa*, commonly known as Onion, contains kampferol, beta sitosterol, ferulic acid, myricic acid, and prostaglandins, (Dhanprakash, *et al.*, 2007). It has anti-diabetic, antioxidant, (Compos *et al.*, 2003), anti-hypertensive, (Murakami, *et al.*, 2003), antithrombotic, (Yamada, *et al.*, 2004), hypoglycemic and hypolipidemic properties, (Saxena, *et al.*, 1991). Locally, it is used as food, diuretic, anti-allergic, anti-oxidants, and anti-bacterial agent. It is used in the management of insect sting, colds, cough, diarrhea, facial paralysis, hay fever, hernia, laryngitis, pneumonia and trauma, (Hwang, *et al.*, 2002; Racci, *et al.*, 2002).

*Verbena Officinalis L.*, known locally as Vervain, contains dihydro-verbenalin and daucosterol, (Zhang, *et al.*, 2000), apigenin, 4'-hydroxywogonin, verbenalin and hastatoside (Tian *et al.*, 2005),  $\beta$ -sitosterol, ursolic acid,

oleanolic acid, 3-epiursolic acid, 3-epioleanolic acid, and minor triterpenoids of derivatives of ursolic acid and oleanolic acids. Chromatographic purification of the methanol extract of *V. Officinalis* yielded two iridoid glucosides, verbenalin and hastatoside, a phenylpropanoid glycoside, verbascoside and  $\beta$ -sitosterol-D-glucoside, (Deepak and Sukhdev, 2000). It is reported to exhibit anti-oxidant and antifungal properties, (Casanova, *et al.*, 2008), anti-inflammatory, analgesic, and anti-tussive activities, (Speroni, *et al.*, 2007, Deepak and Sukhdev, 2000), and promote factor-mediated axon growth (Sau-Wan, *et al.*, 2006). Locally it is used as anti-coagulant, anti-tannins, diuretic, stimulant, tonic, astringent, and diaphoretic agent.

*Marrubium vulgare* L., (locally known as white horehound), is used as an expectorant, appetite stimulant, choleric, and in the management of dyspepsia. Pharmacologically, it has been confirmed to have hypotensive activity, (Bardai, *et al.*, 2001), antinociceptive, (De Jesus, *et al.*, 2000), hypoglycemic, (Novaes, *et al.*, 2001; Roman, *et al.* 1992), and vasorelaxant activities, (El Bardai, *et al.*, 2003).

Gamma globulins are a class of proteins in the blood, which has been found useful as immune boosters, (<http://en.wikipedia/wiki/Gammaglobulin>).

*Lactuca Virosa*, (Commonly known as Wild lettuce, and bitter lettuce), has been used locally for its galactagogue, psychotropic, anesthetic and hypnotic properties. It contains lactucin and lactucopicrin, and sesquiterpene lactones, (Schenck, *et al.*, 1939). Pharmacological evaluation revealed that its constituents possess mild sedative, analgesic, and cough suppressant activity, (Wesołowska, *et al.*, 2005).

*Eucalyptus globus*, (known locally as Blue gum), is rich in Eucalyptus oil, a substance that has been confirmed to have anti-inflammatory, anti-bacteria, (Salari, *et al.*, 2006), and analgesic properties, (Gobel, *et al.*, 2002). Eucalyptus oil has a wide range of uses; its main use is in the control of nasal congestion and the management of bronchitis, (Lu XQ, *et al.*, 2004). *E. globus* is also used for the management of bacterial infection, diabetes, pain, allergic reactions/ hay fever, sinusitis, arthritis, and laryngitis. Locally it is used as an expectorant, astringent, anti-inflammatory agent, and as insect repellent. Apart from Eucalyptus oil, it also contains cineole, pinenes sesquiterpene alcohols, and aromadindrene cuminaldehyde, (Annie's Remedy 2008; <http://en.wikipedia.org/wiki/eucalyptus>).

*Solanum lycopersicum*, a plant known with the household name -Tomato, is an ingredient in almost every meal, and is rich in lycopine (a heart protective substance), (Badmus, *et al.*, 2009). The leaves, stem and green unripe fruit of tomato plant contained small amount of the poison alkaloid tomatine (Barceloux, 2009). Tomato leaves in the form of tea have been linked to at

least one death, (Pittenger, 2002), but the level of tomatine is generally too small to constitute health problems, (Mcgee, *et al.*, 2009).

*Tilia cordata*, M., (known locally as Linden), contains mucila polysaccharides, tannis, flavonoids, quercetin and akaempferol glycoside, phenolic acid and essential oil, (Bradley, 1992; Newall, *et al.*, 1996). It is reported to have antispasmodic, diaphoretic, sedative, hypotensive, emollient and mildly astringent actions (Bradley, 1992). Traditional medical practitioners use it for the management of cold, cough, fever, (Bradley, 1992), infections, inflammation, high blood pressure, headache (particularly migraine), and as diuretic, antispasmodic, and sedative agent. New evidence shows that the flowers of *tilia* species may be hepatoprotective, (Matsuda, *et al.*, 2002). This work seeks to investigate and ascertain the safety profile of the herbal cough mixture (HAMEKOF) in rats.

## MATERIALS AND METHOD

The Kit test methods was used for biochemical assay, kits used include; urea test kit (fortress diagnostics), creatinine test kit (fortress diagnostics), AST test kit (fortress diagnostics), ALT test kit (fortress diagnostics), protein test kit (fortress diagnostics), sodium test kit (linear chemicals, s. l.), calcium test kit (linear chemicals, s.l.), potassium test kit (fortress diagnostics), triglycerides test kit (fortress diagnostics), and albumin test kit (rx monza).

### Collection of herbal preparation

Freshly prepared herbal product (Hamekof) was obtained from Hameko naturalist Hospital LTD in 2010 by Mr. Patrick O. Olurunfemi of the Department of Pharmaceutical Microbiology, University of Jos, Jos, Plateau State, Nigeria. Hamekof was stored at room temperature in the laboratory cabinet till use. Composition of Hamekof was obtained from the manufacturer and compared with listed contents on the product label. The product contains nine (9) plants, gamma globulin and water.

### Animals

Male wistar albino rats (160 - 230 g) obtained from the animal house of the Department of Pharmacology University of Jos were used for this study. The rats were fed on standard laboratory diet, given water *ad libitum* and maintained under laboratory conditions of temperature  $28 \pm 1^\circ\text{C}$ , relative humidity  $11 \pm 1\%$  and 12 h

light and 12 h dark cycle.

### Acute toxicity (LD50) study

Acute toxicity study was evaluated using the method describe by Matsuda, et al., 2002. After the acute toxicity studies, treated rats were observed daily for seven days for signs of toxicity, which include, but not exclusive to paw-licking, salivation, stretching on the floor and wall of cage, and death. The mean lethal dose was calculated and noted.

### Sub-acute toxicity study

Sub-acute toxicity study was evaluated using the method described by Otimenyin, *et al.*, (2010). Briefly, the rats were divided into two groups with 5 rats each, group A received hamekof, 1000 mg/Kg (orally) daily for 28 days, while group B, (control) were given 10 ml/kg of distilled water daily for 28 days. Daily body weights of the rats and signs of toxicity were monitored during the period of administration. After 28 days, animals were allowed to fast overnight, anaesthetized with petroleum ether and blood samples were collected from the rats via cardiac puncture into heparinized tubes (for hematological analysis) and non-heparinized centrifuge tubes (for biochemical analysis). Treated animals were then sacrificed to allow for the isolation of the liver, kidneys, lungs, testis, stomach and heart. Isolated organs were weighed and preserved in 40 % formalin for histopathological studies.

### Haematological studies

Haematological analysis was carried out using standard physiological methods, (Rinder and Dabieh, 1979), as briefly described by Otimenyin, *et al.*, 2013.

### Biochemical Studies

Blood samples were collected by cardiac puncture with the aid of syringe, transferred into centrifuge bottle, and centrifuged at 4000 rpm for 15 minutes until the serum was partitioned from blood cells. Serum was harvested and stored in the refrigerator till use. Biochemical assay were carried out using kit methods, (Otimenyin, *et al.*, 2010).

### Histopathological studies

The Liver, Kidney, Heart, Lungs, Spleen, and Stomach were isolated from sacrificed animals, grossly examined

for any pathological changes and then fixed in 10 % saline for 5 days at room temperature. The method described by Otimenyin, *et al.*, 2013, was used to obtain slides of the different organs for examination under the microscope.

### Statistical analysis:

Results were expressed as mean  $\pm$  SEM. Statistical analysis of data was carried out using one –way analysis of variance and students T- test. Significant differences were determined using a Student's t-test and the differences were considered significant if  $p < 0.05$ .

## RESULTS

### Effect of hamekof on the weight of body organs

Organ weight/ body weight ratio of the treated were not significantly different from that of the control, (Table 1).

### Effect of Hamekof on Haematological parameters in Rats

Slight insignificant increase was observed in neutrophils, eosinophils and monocyte in the treated rats. Clotting time of treated animals was much lower ( $P < 0.05$ ) in treated rats, (Table 2).

### Effect of hamekof on liver enzymes

Herbal cough mixture (Hamekof) caused a significant increase in aspartate aminotrasaminase (AST), Table 3, and an insignificant increase in alanine aminotransamise (ALT) and alkalino phosphatase(ALP).

### Effect of hamekof on body weight of rats

Rat's body weight was increased after the oral administration of Hamekof, but the changes in body weights were statistically insignificant ( $p < 0.05$ ) when compared with the control, (Table 4).

### Effect of hamekof on biochemical assay

The effect of herbal cough mixture (Hamekof) on the various biochemical parameters: urea, albumin, cholesterol, sodium, triglyceride, calcium, creatinine, total protein and potassium are shown in Table 5.

There was significant change ( $p < 0.05$ ) in the values of urea, sodium, (values were lower in treated rats) and

**Table 1.** Effect of Hamekof on organ/body weight ratio of rat weights

		<b>Control</b>	<b>Hamekof</b>
1	Heart/body weight (%)	0.75 ± 0.06	0.58 ± 0.08
2	Liver/body weight (%)	6.25 ± 0.24	5.23 ± 0.39
3	Lungs/body weight (%)	1.23 ± 0.18	1.23 ± 0.13
4	Spleen/body weight (%)	0.73 ± 0.06	0.70 ± 0.11
5	Kidney/body weight (%)	0.70 ± 0.10	0.65 ± 0.05
6	Stomach/body weight (%)	2.65 ± 0.18	2.18 ± 0.2
7	Testis/body weight (%)	1.35 ± 0.06	1.50 ± 0.04

Data are expressed as mean ± SEM n=5 (Students' t-test)

\*Values significant at p<0.05

**Table 2.** Effect of Hamekof on Haematological parameters in Rats

	<b>CONTROL</b>	<b>HAMEKOF</b>	
1	RBC	4.48 ± 0.17	4.28 ± 0.23
2	Hb-conc	17.25 ± 0.17	16.85 ± 0.57
3	PCV	51.75 ± 0.48	50.50 ± 1.66
4	WBC	5.23 ± 0.09	5.50 ± 0.11
5	PLT	85.75 ± 2.02	83.25 ± 1.11
6	CL	52.00 ± 8.84	28.50 ± 9.88*
7	N	44.50 ± 0.65	49.50 ± 1.71
8	L	54.50 ± 1.19	47.75 ± 1.65
9	E	0.40 ± 0.24	0.52 ± 0.31
10	M	0.50 ± 0.29	0.75 ± 0.25
11	B	0.00 ± 0.00	0.00 ± 0.00

Data are expressed as mean ± S.E.M, n=5 (students' t-test)

\*Value significant at p<0.05

RBC – Red Blood Cells (X10<sup>12</sup>/L)

Hb-Conc- Haemoglobin Concentration (g/dl)

PCV – Packed Cell volume (%)

WBC – White Blood Cell (x10<sup>9</sup>/L)

PLT – Platelets (x10<sup>9</sup>/L)

CL – Clotting time (seconds)

N- Neutrophils (%)

L – Lymphocyte (%)

E –Eosinophils (%)

M – Monocytes (%)

B – Basophils (%)

**Table 3.** Effects of 28 days administration of Hamekof hepatic function in rats

	<b>Control</b>	<b>Hamekof</b>
<b>ALP</b>	116.53 ± 21.13	120.88 ± 13.64
<b>ALT</b>	25.67 ± 12.71	40.33 ± 4.10
<b>AST</b>	24.00 ± 17.00	60.00 ± 41.01*

Data are expressed as mean ± S.E.M n = 5 (Students' t-test)

\*Value significant at p<0.05

ALP – Alkaline phosphatase (μ/L)

ALT – Alanine aminotransaminase (u/L)

AST – Aspartate aminotransaminase (u/L)

**Table 4.** Effect of Hamekof on changes in body weight of rats

	Control	Hamekof
Day 1	0.00 ± 0.00	0.00 ± 0.00
Day 7	16.00 ± 0.53	18.00 ± 0.88
Day 14	21.00 ± 1.03	25.30 ± 0.93
Day 21	25.50 ± 1.74	27.50 ± 1.09
Day 28	29.00 ± 1.72	45.00 ± 1.41

Data are expressed as mean ± SEM. n=5 (Students' t-test)

\* Value significant at p<0.05

**Table 5.** Blood chemistry values of rats treated with Hamekof

	Control	Hamekof
Urea (mg/dl)	38.70 ± 4.53	26.80 ± 2.58*
Albumin (g/dl)	4.64 ± 0.56	5.11 ± 0.81
Cholesterol (mg/dl)	153.83 ± 7.26	144.87 ± 12.97
Sodium (mEq/L)	70.46 ± 6.82	56.82 ± 25.00*
Triglyceride (mg/dl)	70.69 ± 6.53	68.70 ± 16.17
Calcium (mg/dl)	6.09 ± 0.53	7.18 ± 0.49*
Creatinine (mg/dl)	0.60 ± 0.05	0.60 ± 0.38
Total protein (g/dl)	12.41 ± 0.35	10.89 ± 2.50
Potassium (mMol/L)	9.33 ± 1.86	9.52 ± 1.05

Data are expressed as mean ± SEM n=5 (Students' t-test)

\*value significant at p<0.05

calcium (values were higher in treated rats), while the values of albumin, cholesterol, triglyceride, creatinine, total protein and potassium in treated rats showed no statistical differences.

### Effect of hamekof on histopathological studies

Photomicrographs of liver, kidney, heart, lungs, spleen, stomach and testis tissue sections stained with haematoxylin and eosin are shown in Figures 1-7.

The tissue sections of the experimental animals were essentially normal when compared with the control sections, Fig 1 – 7. There was no sign of cell lesions or abnormal cell growth.

## DISCUSSION

Herbal medicines have received greater attention as alternative to clinical therapy and the demand for these remedies has currently increased. Experimental screening method is important in other to ascertain the safety and efficacy of traditional and herbal products and also to establish the active component of the herbal products (Kosoki et al., 1987). Herbal medicines are used for a wide variety of medical condition including cough.

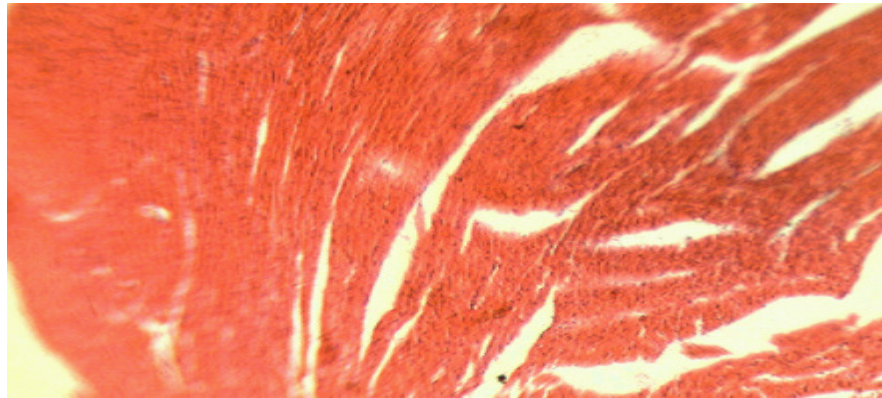
The safety of medicinal plants has been of great concern to scientist and medical doctors. These concerns have necessitated screening of medicinal plants especially those that has been made available in large scale for human consumption. Hamekof is one of such herbal preparation; it contains more than one medicinal plant, suggesting possible herb-herb interaction.

The present study revealed that hamekof did not have significant effect on experimental rat's behavior. The usual sedation or drowsiness observed with most orthodox and herbal cough preparations were absent. Hamekof did not alter the growth changes in body weight during administration, indicating that it will not cause obesity during use. Obesity has been noted as one of the adverse effects of cough remedies and some herbal medicines, (Teo et al., 2002).

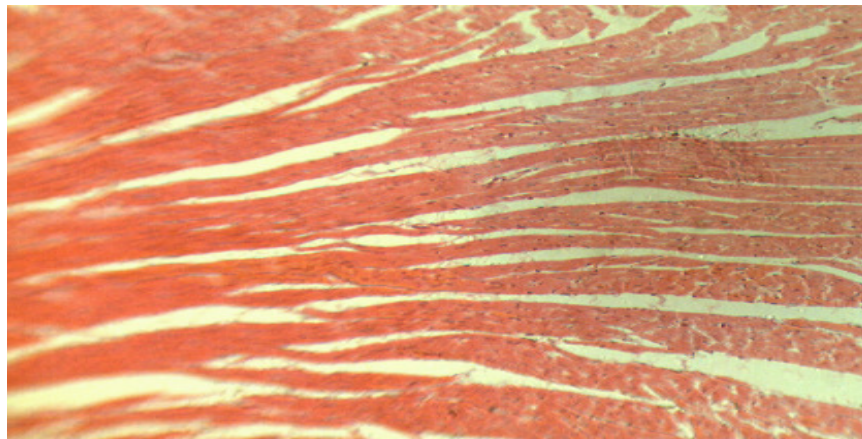
The morphological observations of vital organs such as heart, kidney, liver, spleen, lungs, stomach and testis indicates that there were no signs of inflammation or distortion in the appearance of the organs in treated rats. LD<sub>50</sub> was greater than 2500 mg/Kg. According to the OECD guideline for testing of chemicals, the results of acute toxicity test in this study indicate that the herbal mixture, Hamekof, is fairly non-toxic. Hamekof did not have effect on the blood hemoglobin concentration, packed cell volume and the total RBC, WBC, Platelet, Neutrophils, lymphocytes, eosinophils, basophils, and



**Figure 1.** Effect of hamekof on cardiac cells

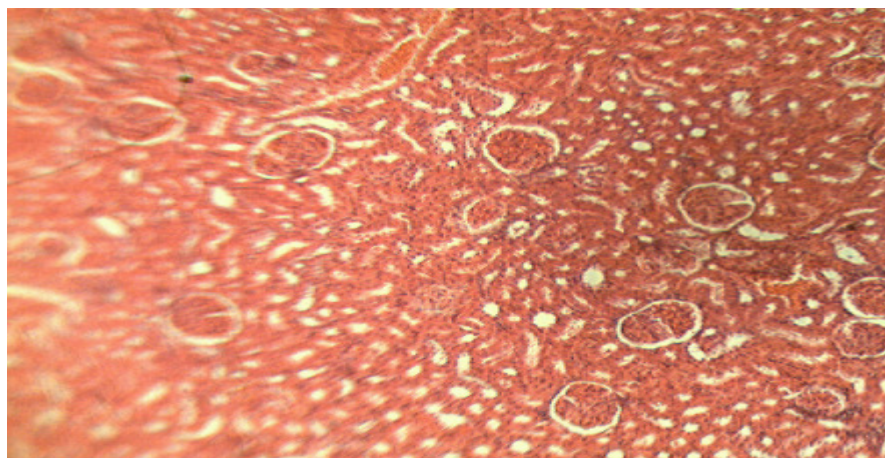


Photomicrograph of cardiac cells for control (magnification x200)

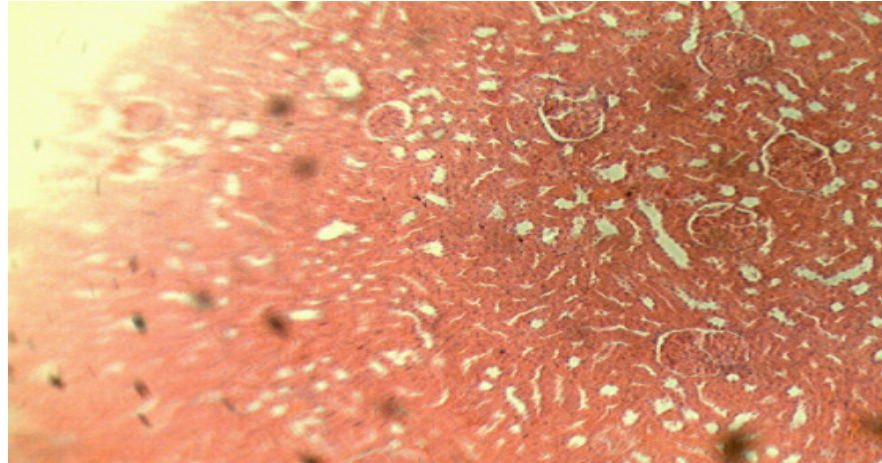


Photomicrograph of cardiac cells for Test (Hamekof) (magnification x200)

**Figure 2.** Effects of hamekof on renal cells

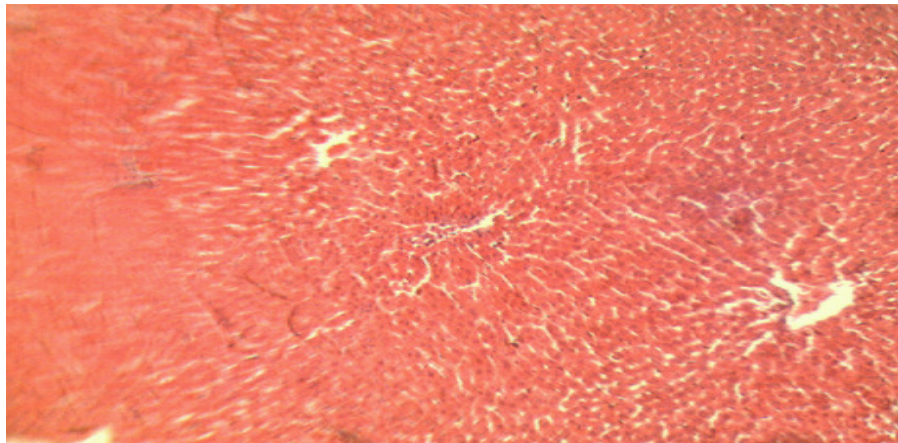


Photomicrograph of Renal cells for control (magnification x200)

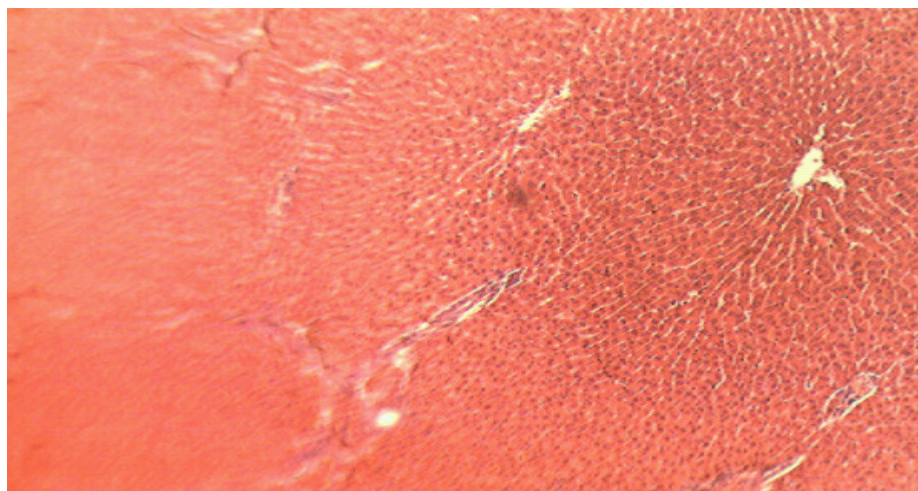


Photomicrograph of Renal cells for Test (Hamekof) (magnification x200)

**Figure 3.** Effect of hamekof on hepatocytes



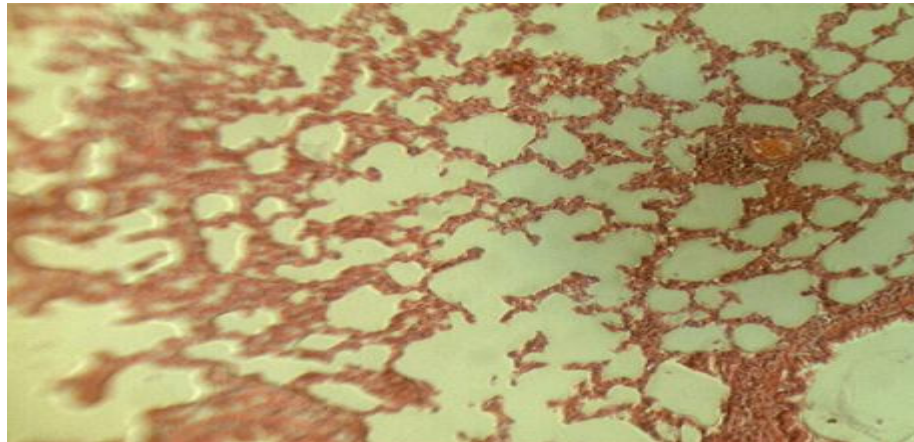
Photomicrograph of Liver cells for control(magnification x200)



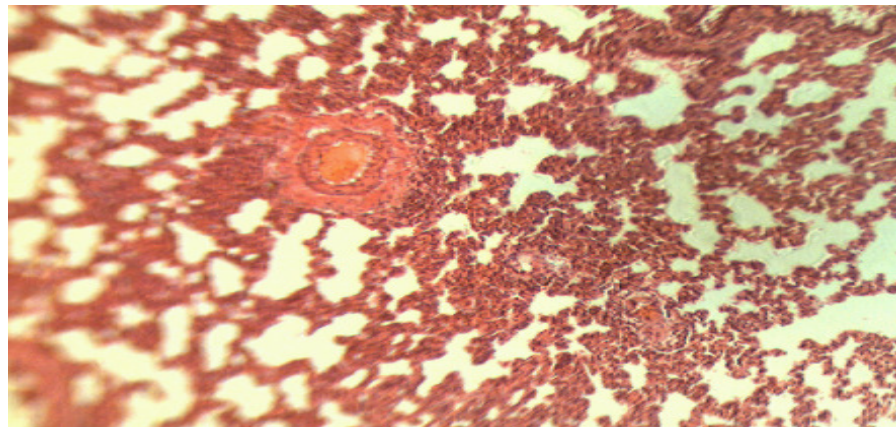
Photomicrograph of Liver cells for Test (Hamekof) (magnification x200)



**Figure 4.** Effect of hamekof on the lungs

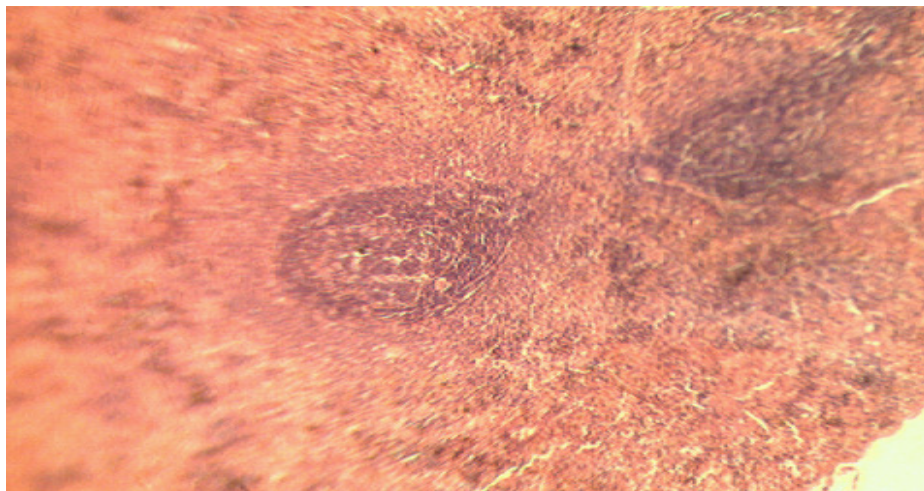


Photomicrograph of the Lungs for control (magnification x200)



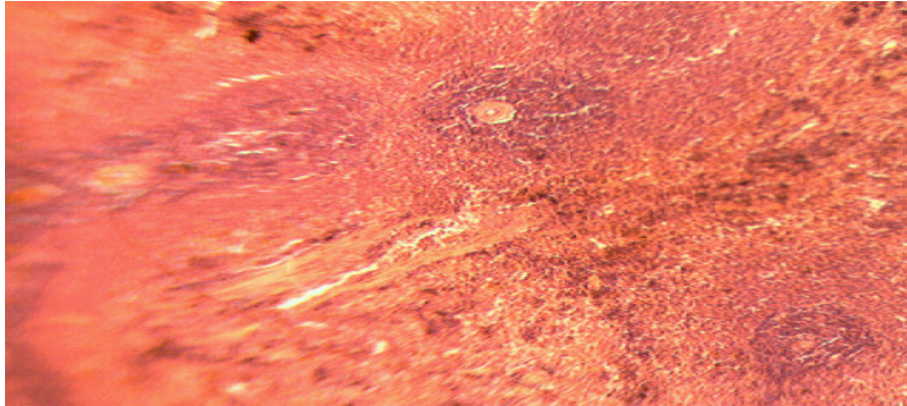
Photomicrograph of the Lungs for Test (Hamekof) (magnification x200)

**Figure 5.** Effect of hamekof on the spleen



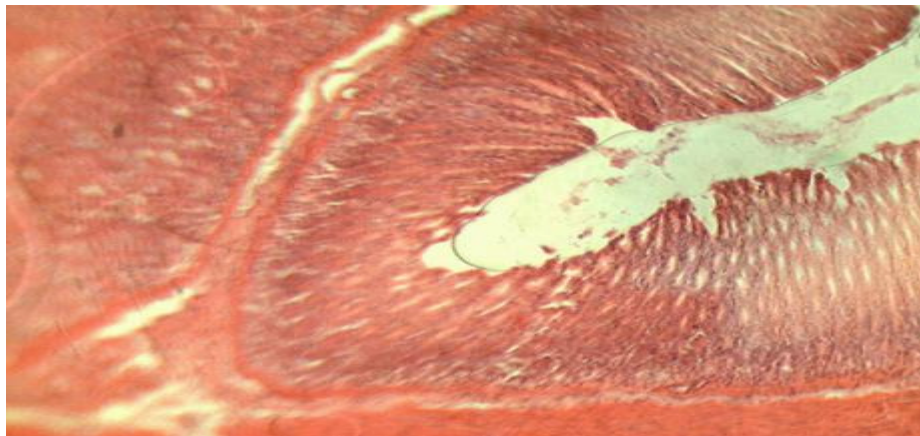
Photomicrograph of the spleen for control (magnification x200)



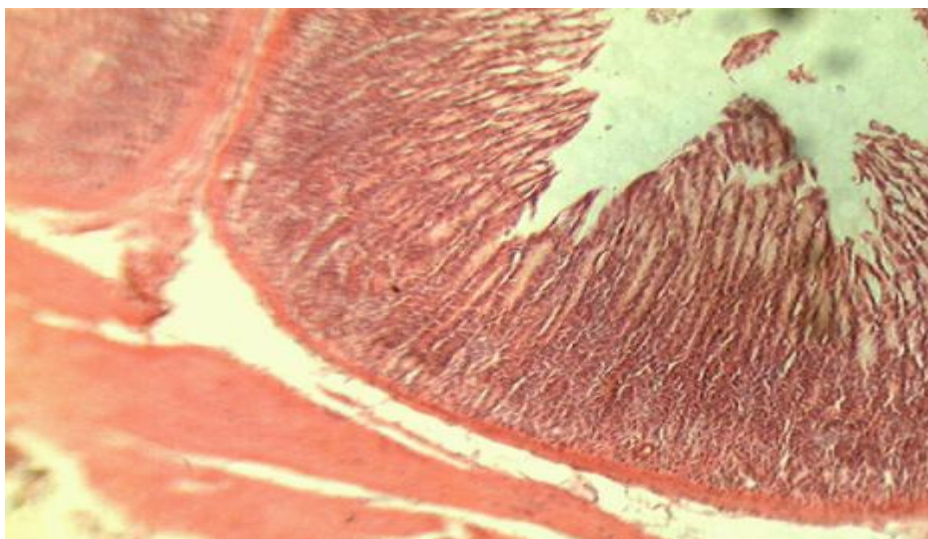


Photomicrograph of the Spleen for Test (Hamekof) (magnification x200)

**Figure 6.** Effect of hamekof on the stomach

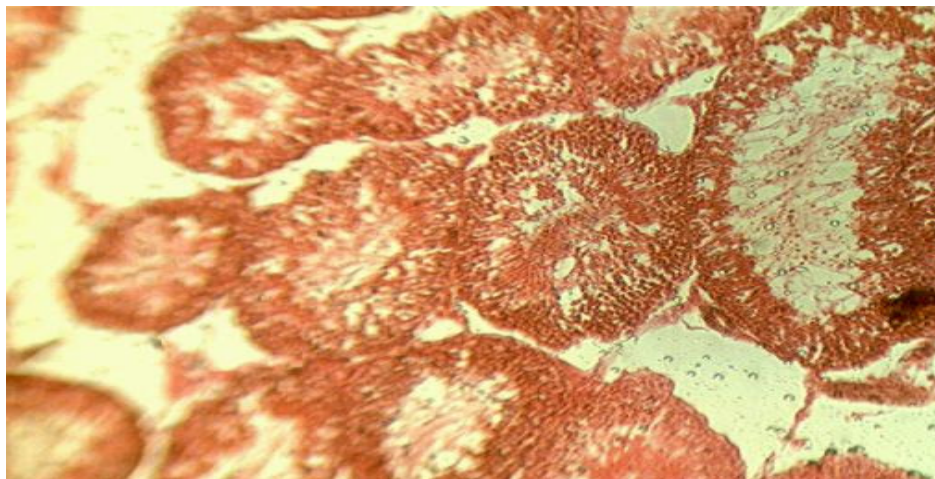


Photomicrograph of the Stomach for control (magnification x200)

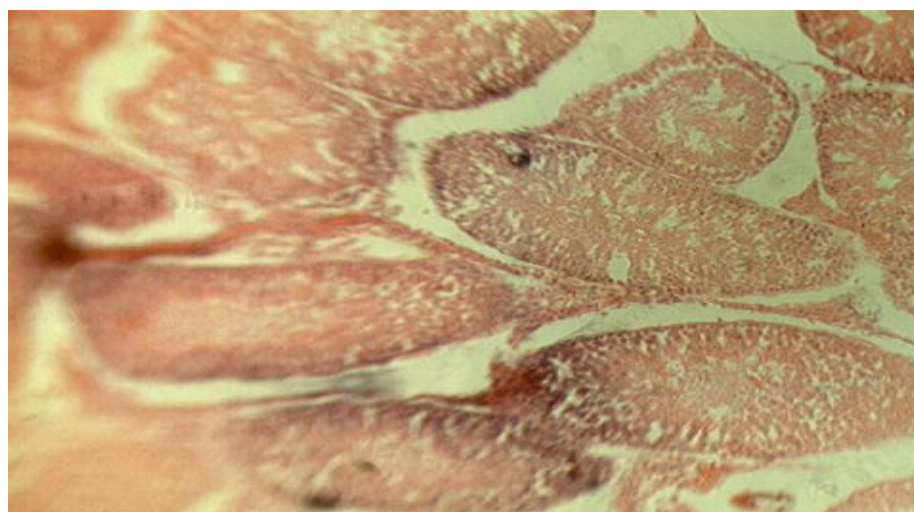


Photomicrograph of the Stomach for Test (Hamekof) (magnification x200)

**Figure 7.** Effect of hamekof on the testis



Photomicrograph of the Testis for control (magnification x200)



Photomicrograph of the Testis for Test (Hamekof) (magnification x200)

monocytes count. The blood clotting time was significantly decreased, indicating that Hamekof has coagulating effect. The reason for this effect is not clear, it is contrary to the effect produced by *Allium cepa*, (one of the herbs in the preparation) an herb that have been reported to have antithrombotic activity, (Yamada et al., 2004). This finding suggests that Hamekof may be contraindicated in geriatric patients, who are prone to cardiovascular disorders.

Blood Neutrophils, lymphocytes, eosiniphils, basophils, and monocytes profile is important in the detection of infection induced by the herbal preparation. Microorganism contaminated herbal preparations may inoculate patients with the contamination organism and raise the blood concentration of Neutrophils, lymphocytes, eosiniphils, basophils, and monocytes,

indicating that the preparation is not safe for consumption. An increase in percentage count of Neurophils is an indication of bacterial infection, while increase in the percentage count of lymphocyte indicates viral infection. Decrease in blood hemoglobin concentration suggests anemia, while a decrease in WBC count suggests a decline in immune system's response to infection. Hamekof did not alter any of these values, an indication that it has good safety profile.

Biochemical parameters (e.g., albumin cholesterol, triglyceride, potassium, total protein) are quantified in individuals to ascertain his health profile. Alteration in the value of the biochemical parameter is an indication that there is a pathological condition. Each of the parameters is tied to different disease conditions. These batteries of biochemical measurements can be used in the diagnosis



of toxicity of drugs on liver, heart and kidney, acid-base imbalance in the respiratory and metabolic systems, others involving lipid metabolism and various endocrine system as well as other metabolic or nutritional disorders. Detailed analysis of the biochemical effects of Hamekof showed that it has good safety profiles, and that it will not predispose the patients to pathological conditions related to the alteration in biochemical parameter. It was observed that hamekof did not significantly alter biochemical parameters assayed, except urea, sodium and calcium. The blood concentration of urea and sodium were significantly decrease compared to the control, an indication that hamekof may be of advantage in patients with gout and / or hypertension respectively. Patients with elevated blood pressure, resulting from the accumulation of sodium are likely to benefit from this preparation. Patients with gout will benefit from its blood urea concentration reducing properties. A slight increase in the level of calcium was observed in the test this was found to be within the normal range for rat i.e 5.3 -12 mg/d (Johnson-Delaney, 1996).

An increase in liver enzymes, (AST, ALT and ALP), is most often associated with hepatocellular damage. In liver disease condition, serum levels of AST and ALT rise and fall in parallel (Sacher and McPherson 1991), only ALT is highly specific for liver function since AST is widely present in myocardium, skeletal muscle, brain and kidney. The increase in AST observed was not significant, as it was within with the normal range for rats i.e. 45.7 – 80.8 u/L, (Johnson Delaney, 1996). ALP was also observed to have slightly increased, but these findings could not be explained from the histopathological results, which showed normal hepatocytes in rats treated with hamekof. The results obtained from biochemical studies supports the histological findings, suggesting that hamekof did not have damaging effects on internal organs.

Gross macroscopical and microscopical examination of the rats' liver, kidney, heart, lungs, spleen, stomach and testis showed that there was no distortion in the shape, size and the cells of the organs of both control and treated rats. This indicates that Hamekof have no effect on the weight, appearance and cells of the internal organs. Hamekof did not cause degeneration of the cells of the organs, (Fig 1 – 7). Toxic herbal preparations are withdrawn from the market after few reports of toxicity. These studies supports it's long-term use in Nigerian market and may explain why it has not been withdrawn from Nigerian market.

## CONCLUSION

The herbal cough mixture (Hamekof) did not exhibit toxicity when ingested orally at normal dose (does administered for the management of cough) level. This was evident in the behavior, haematological and

biochemical parameters as well as the histological studies evaluated to determine the toxic potential of the herbal cough mixture. Hence the drug could be said to be safe, further studies is necessary to confirm the efficacy of the preparation in the management of cough.

## REFERENCES

- Badmus Jelili A, Odunola, Oyeronke A, Obuotor Efere M and Oyedapo Oyeboade O (2010). Phytochemicals and *in vitro* antioxidant potentials of defatted methanolic extract of *Holarrhena floribunda* leaves. *African Journal of Biotechnology*. 9 (3), 340-346
- Barceloux DG (2009). "Potatoes, Tomatoes, and Solanine Toxicity (*Solanum tuberosum* L., *Solanum lycopersicum* L.)". *Disease-a-Month*. 55 (6), 391–402
- Bradley P (1992). *British Herbal Compendium*. British Herbal Medicine Association, Dorset (Great Britain). 1, 142–144
- Casanova E, Garcia-Mina JM, Calvo MI (2008). Antioxidant and Antifungal Activity of *Verbena officinalis* L. Leaves. *Plant Foods for Human Nutrition*. September. 63(3), 93-97
- Compos KE, Diniz YS, Cataneo AC, Faine LA, Alves MJ, Nobeli EL (2003). Hypoglycemic and antioxidant effect of onion, *Allium cepa*: dietary onion addition, antioxidant activity and hypoglycemic effect on diabetic rats. *International Journal of Food Sciences and Nutrition*, 54, 241–246
- De Jesus RA, Cechinel-Filho V, Oliveira AE (2000). Analysis of the antinociceptive properties of marrubiin isolated from *Marrubium vulgare*. *Phytomedicine*, 7, 111–115
- Deepak M, Sukhdev SH (2000). Antiinflammatory activity and chemical composition of extracts of *Verbena officinalis*. *Phytotherapy research*. 14 (6), 463 -465
- Dhanprakash BN, Garima U (2007). Antioxidant and free radical scavenging activities of phenols from onion, (*Allium cepa*). *Food Chemistry* 102, 1389–1393
- El Bardai S, Lyoussi B, Wibo M (2001). Pharmacological evidence of hypotensive activity of *Marrubium vulgare* and *Foeniculum vulgare* in spontaneously hypertensive rat. *Clin Exp Hypertens* . 23, 329–343
- El Bardai S, Morel N, Wibo M (2003). The vasorelaxant activity of marrubenol and marrubiin from *Marrubium vulgare*. *Planta Med*. 69, 75–77
- El-Fiky, Fathy K, Abou-Karam, Mohamed A, Afify Elham A (1996). Effect of *Luffa aegyptiaca* (seeds) and *Carissa edulis* (leaves) extracts on blood glucose level of normal and streptozotocin diabetic rats. *Journal of Ethnopharmacology*. 50 (1): 43-47
- Göbel H, Schmidt G, Soyka D (2002). Effect of peppermint and eucalyptus oil preparations on neurophysiological and experimental algesimetric headache parameters, *Cephalalgia*. 14 (3), 228–234
- Hwang YH (2002). "Suspended Onion Particles and Potential Corneal Injury in Onion Harvesters." *Archives of Environmental Health*. 57, 78-84
- Jen-Hsou Lin, Phil Rogers, Haruki Y (1998). Integration of ancient and modern medicine towards a sustainable system of animal production and medical care. Paper to the 24<sup>th</sup> IVAS Congress, Chitou, Taichung, Taiwan.
- Johnson-Delaney C (1996). *Exotic Companion Medicine Handbook for Veterinarians (2 Vol. Set)*. Lake Worth, FL: Zoological Education Network.
- Lata S, Saxena KK, Bhasin V, Saxena RS, Kumar A, Srivastava VK (1991). Beneficial effects of *Allium sativum*, *Allium cepa* and *Commiphora mukul* on experimental hyperlipidemia and atherosclerosis--a comparative evaluation. *Journal of Postgraduate medicine*. 37 (3), 132-135
- Lorke D (1983). A new approach to practical acute toxicity testing. *Arch.Toxicol*. 54; 275-287.
- Lu XQ, Tang FD, Wang Y, Zhao T, Bian RL (2004). Effect of Eucalyptus globulus oil on lipopolysaccharide-induced chronic bronchitis and



- mucin hypersecretion in rats, *Zhongguo Zhong Yao Za Zhi*, 29(2), 168–171
- Matsuda H, Ninomiya K, Shimoda H and Yoshikawa M (2002). Hepatoprotective principles from the flowers of *Tilia argentea* (linden): structure requirements of tiliroside and mechanisms of action. *Bioorg Med Chem*. 10 (30): 707–712
- McGee, H (2004). *On Food and Cooking: The Science and Lore of the Kitchen*. New York, NY: Scribner. 367
- Neltje, B (2002). *Wild Flowers: An Aid to Knowledge of our Wild Flowers and their Insect Visitors*. Project Gutenberg Literary Archive Foundation
- Newall C (1996). *Herbal Medicines A Guide for Health-Care Professionals*, The Pharmaceutical Press, London. 1996
- Ng TB, Wong RN, Yeung HW (1992). Two proteins with ribosome-inactivating, cytotoxic and abortifacient activities from seeds of *Luffa cylindrica* roem (Cucurbitaceae). *Biochem Int*. 27(2): 197-207
- Ng TB, Chan WY, Yeung HW (1992). Proteins with abortifacient, ribosome inactivating, immunomodulatory, antitumor and anti-AIDS activities from Cucurbitaceae plants. *Gen Pharmacol*. 23(4): 579-590
- Novaes AP, Rossi C, Poffo C. (2001). Preliminary evaluation of the hypoglycemic effect of some Brazilian medicinal plants. *Therapie*. 56, 427–430
- OECD Guideline for Testing of Chemicals, 1981. Organization for Economic Cooperation and Development.
- Otimenyin SO, Olorunfemi PO, Audu OM, Sabo S (2013). Sub-acute toxicity study of herbal blood tonic (hamebuild) in albino rats. *Asian Journal of Pharmaceutical & Clinical Research*; 2 (6). p78
- Otimenyin SO, Kolawole JA and Nwosu M (2010). Pharmacological basis for the continual use of the root of *sennasiamea* in traditional medicineinternational. *Journal of pharma and bio sciences*, 1(3); 1-9.
- Pittenger, Dennis R (2002). "Vegetables That Contain Natural Toxins". *California Master Gardener Handbook*. ANR Publications. 643–644
- Poma A, Miranda M, Spanò L (1998). Differential response of human melanoma and Ehrlich ascites cells in vitro to the ribosome-inactivating protein luffin. *Melanoma Res*. 8(5): 465-467
- Racchi M (2002). "Antiradical Activity of Water-Soluble Components in Common Diet Vegetables." *Journal of Agricultural and Food Chemistry*. 50, 1272-1277
- Ringer DH and Dabieh L (1979). Haematology and clinical Biochemistry. In: the laboratory Rats. Vol.1, edited by Baker HJ, Lindsey HJ, Weisbroth SH. Academic press, London, pp. 105-116.
- Roman Ramos R, Alarcon-Aguilar F, Lara-Lemus A (1992). Hypoglycemic effect of plants used in Mexico as antidiabetics. *Arch Med Res* . 23, 59–64
- Sacher RA, McPherson RA (1991). *Widmann's Clinical Interpretation of Laboratory Test*. Pennsylvania, USA, pp. 416–443.
- Sakai Y, Murakami T, Yamamoto Y (2003). Antihypertensive effects of onion on NO synthase inhibitor- induced hypertensive rats and spontaneously hyperthensive rats. *Biosci., Biotechnol., Biochem*. 67; 1305- 1311
- Salari MH, Amine G, Shirazi MH, Hafezi R, Mohammadypour M (2006). Antibacterial effects of *Eucalyptus globulus* leaf extract on pathogenic bacteria isolated from specimens of patients with respiratory tract disorders. *Clin. Microbiol. Infect*. 12, 178–196
- Sangh P, Amit K, Neeraj KS, Jha KK (2012). *Luffa Cylindrica* : An important medicinal plant. *J. Nat. Prod. Plant Resour.*, 2 (1): 127-134
- Sau-Wan Lai, Man-Shan Yu, Wai-Hung Yuen (2006). Novel neuroprotective effects of the aqueous extracts from *Verbena officinalis* Linn, *Neuropharmacology*. 50 (6), 641–650
- Schenck G, Graf H, Schreiber W (1939). *Archiv der Pharmazie* 277, 137-145
- Speroni E, Cervellati R, Costa S, Guerra MC, Utan A, Govoni P, Berger A, Müller A, Stuppner H (2007). Effects of differential extraction of *Verbena officinalis* on rat models of inflammation, cicatrization and gastric damage. *Planta Med*. 73(3), 227-35
- Teo S, Stirling D, Thomas S, Hoberman A, Kiorpes A, Khetani V (2002). A 90-day oral gavage toxicity study of d-methylphenidate and d,l-methylphenidate in Sprague Dawley rats. *Toxicology* 179, 183–196.
- Tian J, Zhao YM, Luan XH (2005). Studies on the chemical constituents in herb of *Verbena officinalis*. *Zhongguo Zhong Yao Za Zhi*. 30(4), 268-9.
- Wesolowska A, Nikiforuk A, Michalska K, Kisiel W, Chojnacka-Wójcik E (2006). Analgesic and sedative activities of lactucin and some lactucin-like guaianolides in mice. *J Ethnopharmacol*. 107(2), 254-258
- Yamada K, Naemura A, Sawashita N, Noguchi Y, Yamamoto J (2004). An onion variety has natural antithrombotic effect as assessed by thrombosis/thrombolysis models in rodents. *thrombosis Res*. 114:213-220
- Zhang T, Ruan JL, Lu ZM (2000). Studies on chemical constituents of aerial parts of *Verbena officinalis* L. *Zhongguo Zhong Yao Za Zhi*. 25(11), 676-8.

How to cite this article: Otimenyin SO, Olorunfemi PO., Sabo YS and Attah SH (2013). Sub acute toxicity studies of the herbal cough mixture (hamekof) in adult male wister rats. *J. Med. Med. Sci.* 4(11):439-450