

## Case Report

# Ipsilateral fibrosarcoma following recurrent post traumatic femoral fracture

Amupitan Idumagbodi, Onche Icha, Misanuo Micheal<sup>1</sup>

Departments of Orthopedics and Trauma and <sup>1</sup>Surgery, Jos University Teaching Hospital, Jos, Jos Plateau State, Nigeria

### Address for correspondence:

Dr. Amupitan Idumagbodi,  
Department of Orthopedics, Jos University Teaching Hospital, 2076, Jos, Jos Plateau State, Nigeria.  
E-mail: Idumagbodi@yahoo.com

### ABSTRACT

The aetio-pathogenesis as with most malignancies is not known. However, trauma has been proposed as a possible theory underlying the development of this malignancy, where it is believed that the reparative cells could undergo malignant transformation. There is however a paucity of data suggestive of this theory in our setting. Hence this case report in the above case report the question is whether the recurrent trauma and subsequent surgery is coincidental with the development of the malignancy. This report highlights the possibility of such occurrences.

**Keywords:** Femoral fractures, fibrosarcoma, malignancy

### Introduction

Fibro sarcoma occurs rather infrequently and is associated with poor prognosis; however, it could be curable if the patient presents early. Malignancies occurring after repeated femoral fracture and implant surgeries are generally rare and in frequently reported literature and to the best of our knowledge this is the first with such an unusual presentation in the sub region.

The aim of the case presentation is to highlight the possibility of malignancy occurring with repeated femoral fractures.

### Case Report

A 34-year-old, male, soldier, who presented with a two-day history of swelling, deformity and abnormal movement of the distal third of the left thigh following a motorcycle road traffic accident, and no other injuries to any other system.

There was a past history of fracture in the same limb eighteen months earlier which was treated by traditional bone setters [Figure 1].

### Access this article online

#### Quick response code



**Website:**  
[www.joas.in](http://www.joas.in)

**DOI:**  
10.4103/2319-2585.153983

Clinical and radiological examinations confirmed femoral fracture in the distal third of the femur through the site of the previous fracture [Figure 2]. The bone was essentially normal. He was prepared and had open reduction and internal fixation (ORIF) USING A RETROGRADE, reamed, interlocking femoral nail. Both preoperative X-rays and findings intra operatively did not show any abnormal pathology.

Post-operative period was uneventful; he was subsequently discharged on bilateral axillary clutches, non-weight bearing on the affected side.

He presented four months later with a rapidly progressive distal third left thigh swelling with associated weight loss, anorexia and occasional fever.

Examination revealed a young man that was chronically ill looking, wasted and pale.

Musculoskeletal examination revealed a circumferential swelling of the distal third of the left femur, measuring 55 cm compared with 45 cm on the contralateral thigh [Figure 3]. The skin was shiny with a healed linear scar on the lateral aspect as the swelling was warm to touch, tender, and firm in consistency. The surface was smooth, with well-defined edge, attached to the underlying structure but not to the skin; no regional lymphadenopathy and distal neurovascular integrity was intact within the ability to bear weight on the same limb. Other systemic examination was not contributory.

Investigation results showed; packed cell volume - 35%, Total white blood cell count-  $6.8 \times 10^{12}$ , PLTC-  $380 \times 10^9$ , Neutrophils-60%, Lymphocytes- 36%, HIV and hepatitis B surface antigen screening was negative, electrolyte urea and creatinine assay were within normal limit. So also was the liver function test. Abdominal ultrasound showed hepatomegaly. Chest x-ray showed features of cannon ball metastasis; X-ray of the left thigh showed marked soft tissue swelling with some area [Figure 4] of calcification, with an indwelling interlocking nail and minimal callous formation at fracture site.

He had an open biopsy done which on histology showed fibrocellular stroma with neoplastic spindle cell arranged in stariform pattern consistent with a fibro sarcoma.

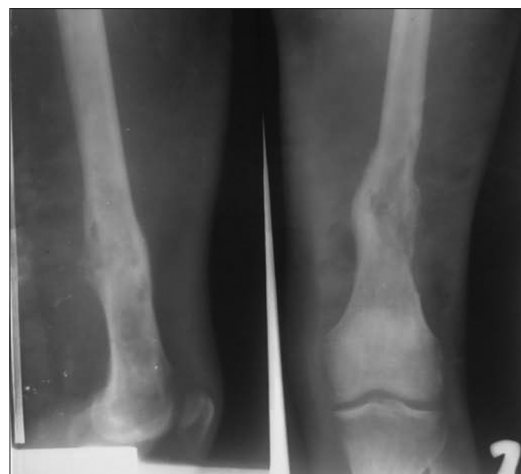Patient was commenced on neo adjuvant single agent chemotherapy with adriamycin to which he responded initially but later died from respiratory failure due to pulmonary metastasis after two months on admission.

## Discussion

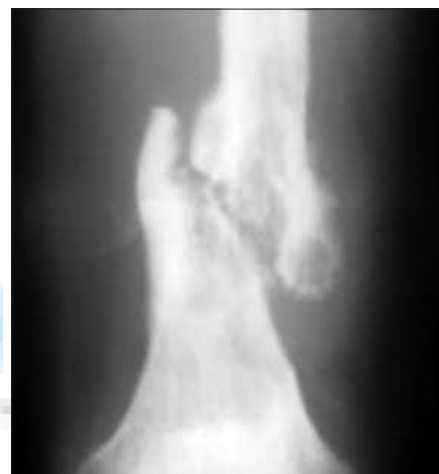Fibrosarcoma is a malignant neoplasm arising from fibroblast; grossly, it is a firm greyish mass of tissue that is well-encapsulated, and is often confused with other malignancies e.g., synovial sarcoma, and osteogenic sarcoma. Fibrosarcoma has been reported to occur in almost all regions of the body but those occurring on the extremities have the highest incidence, with the thigh being the most common site.<sup>[1]</sup> The cause of fibrosarcoma is not known; however, a number of etiological factors have been proposed among which is a trauma. Ivrin *et al.*, found this relationship in one out of 78 cases,<sup>[2]</sup> while Brindley *et al.*, found 3 out of 45 cases (6.7%),<sup>[1]</sup> although Ariel in his series of 39 patients reported no such relationship.<sup>[3]</sup> Other factors implicated, include malignant transformation arising from a benign lesion, congenital and hereditary factors. Some have however been reported to occur in draining sinuses and at foci of chronic osteomyelitis.<sup>[4]</sup> A few cases of malignancy arising from metallic implant have been reported but the numbers are quite small in comparison with the number of implants inserted such that the risk can probably be discounted.<sup>[5]</sup> There is however the need to highlight the possibility of such occurrences so that surgeon involved in the management of patients with metallic implant should have a high index of suspicion during follow-up. Most especially that trauma and metallic implant post a dual risk.

Femoral fracture occurs as a result of trauma, which is said to be the second most commonly fractured bone and for most patients in our environment the traditional bone setter is the first point of call as in the index patient.<sup>[6,7]</sup> Healing is often associated with malunion and scar tissue formation, which could act as a trigger for malignant transformation.

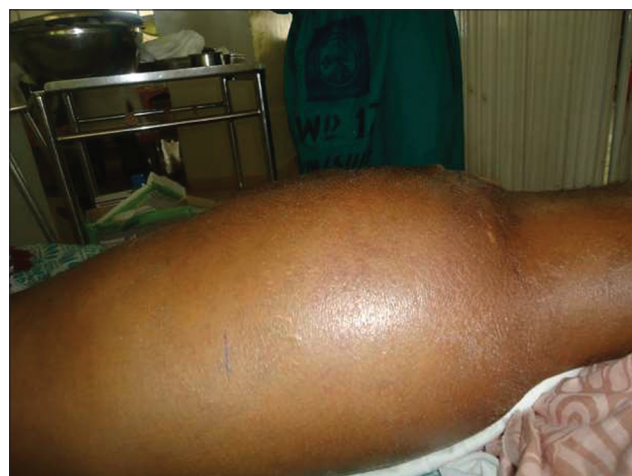Most patients with fibro sarcoma are often unaware and present late, with recurrence or large swelling that could be initially mistaken as a benign lesion



**Figure 1:** X-ray taken after initial management by traditional bone setters



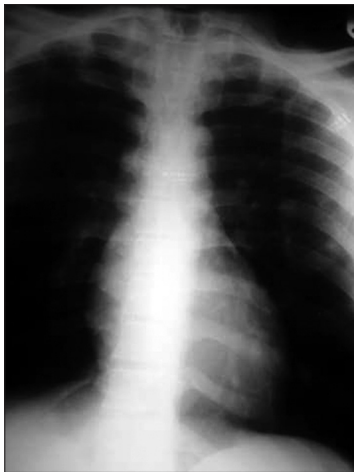**Figure 2:** (X-ray at presentation)



**Figure 3:** Clinical picture at representation

## Conclusion

In the above case, the question is whether the presence of the



**Figure 4:** Chest X-ray with cannon ball metastasis


recurrent trauma with associated femoral shaft fracture and metallic implant and the fibro sarcoma is a coincidental finding. We think so although no biopsy was performed at the time of implant surgery because there was no clinical evidence to suggest that as such we cannot rule out the possibility of such incidence.

## References

1. Brindley HH, Philips C, Fernandez JN. Fibrosarcoma of the extremities review of forty-five cases. *J Bone Joint Surg* 1955;37:602-8.
2. Oscar D, Paul CJ. Etiologic factors in fibrosarcoma. *J Med Case Rep* 2010:198.
3. Pack GT, Aerial IM. Fibrosarcoma of the soft tissues; A clinical and pathological study. *Surgery* 1952;31:443-78.
4. Akbernia BA, Wirth CR, Colman N. Fibrosarcoma arising from chronic osteomyelitis. Case report and review of literature. *J Bone Joint Surg* 1976;58:123-5.
5. Naiyagam. S, Principles of fractures management. *Apleys System of Orthopedics and Fractures*. 9<sup>th</sup> ed. 2010. p. 687-732.
6. Dada AA, Yinusa W, Giwa SO. Review of the practice of traditional bone setting in Nigeria. *Afr Health Sci* 2011;11:262-5.
7. Owoola AM, Thanni LO. Epidemiology and outcome of limb fractures in Nigeria: A hospital based study. *Niger J Orthop Trauma* 2012;11:67-101.

How to cite this article: Idumagbodi A, Icha O, Micheal M. Ipsilateral fibrosarcoma following recurrent post traumatic femoral fracture. *J Orthop Allied Sci* 2015;3:25-7.

Source of Support: Nil, Conflict of Interest: None declared.



## New features on the journal's website

### Optimized content for mobile and hand-held devices

HTML pages have been optimized of mobile and other hand-held devices (such as iPad, Kindle, iPod) for faster browsing speed. Click on [**Mobile Full text**] from Table of Contents page.

This is simple HTML version for faster download on mobiles (if viewed on desktop, it will be automatically redirected to full HTML version)

### E-Pub for hand-held devices

EPUB is an open e-book standard recommended by The International Digital Publishing Forum which is designed for reflowable content i.e. the text display can be optimized for a particular display device.


Click on [**EPub**] from Table of Contents page.

There are various e-Pub readers such as for Windows: Digital Editions, OS X: Calibre/Bookworm, iPhone/iPod Touch/iPad: Stanza, and Linux: Calibre/Bookworm.

### E-Book for desktop

One can also see the entire issue as printed here in a 'flip book' version on desktops.

Links are available from Current Issue as well as Archives pages.

Click on  View as eBook