

## FRACTURE OF THE PENIS A REPORT OF TWO CASES

BT Ugwu, HU Liman, AA Sani, AM Mohammed

Department of Surgery, Jos University Teaching Hospital, Jos, Nigeria.

### ABSTRACT

We present two cases of fracture of the penis in two young men at the extremes of the social strata the first an unemployed tailor while the other a practicing engineer. The first one was a bachelor while the other was married with children. In the first case, the fracture occurred during masturbation while in the second case it occurred during consensual intercourse with his wife on top. In the first case the fracture occurred at the base of the penis with associated rupture of the deep dorsal vein while in the second case it affected the mid-shaft with urethral rupture and blood at the tip of the penis at presentation. Both of them presented within two hours of their injuries with deformed, swollen and tender penis. Laubscher's subcoronal sleeve operation with evacuation of clots and repair of the tear with absorbable sutures to ensure a leak-proof repair was promptly performed with no complications. Both patients experienced spontaneous erection whilst in hospital even with indwelling catheter in place. The wife of the second case became pregnant six months after the repair. Counseling was successful with the engineer but was unsuccessful with the tailor-bachelor who continued with masturbation despite professional help. Though we published the first case of fracture of the penis in this centre almost a decade ago, we still found it necessary to report these new cases managed after we created awareness of this uncommon condition in our environment in order to highlight the presentations and the factors that influenced outcome.

**Key Words:** Fracture, penis, injury, masturbation

*(Accepted 15 April 2008)*

### CASE REPORT

**Case 1.** A 41 years old unemployed tailor, a bachelor, walked into the Accident & Emergency of Jos University Teaching Hospital, Jos, Nigeria with a painful, right sided swelling and deformity of his penis following masturbation. He had stabilized the root of his penis with the thumb and index of his left hand and rotated the penis toward the left with his right hand as was his practice. This time he heard a click sound which was quickly associated with pain, detumescence, and deformity of the penis. He was promptly evaluated and had Laubscher's subcoronal sleeve operation with evacuation of blood clots and repair of the corporal tear transversely with 3-0 polyglactin (Vicryl) absorbable sutures as shown in figure 1. He made remarkable recovery and reported spontaneous erection without angulations on the 5<sup>th</sup> post-operative day. He had professional counseling for three months but defaulted when counseling could not stop his masturbation. He had been followed up for nine months without complications.

**Case 2.** A 35 years old civil engineer presented with a painful, deformed penis with blood at the tip of the Penis at the Accident & Emergency unit. He had been accompanied by his wife who corroborated his history that the injury occurred during a vigorous sex act with his wife on top. This was follow by pain, detumescence, deformity and blood at the tip of his penis as shown in figure 2. He was prepared for

surgery and had Laubscher's subcoronal sleeve operation, exposing the tear in the mid shaft of the corpus cavernosum and a bruised urethra with a 0.5 cm transverse tear of the urethra. There was no tear at the root of the penis. The corporal tear was repaired transversely with a 3-0 polyglactin (Vicryl). The urethra was catheterized under direct vision to serve as a stent as shown in figure 3. He made an uneventful recovery and was followed up for one year without urethral stricture or other complication. He achieved full erection without angulations seventh post-operative day and his wife became pregnant six months after surgery. He found counseling useful in preventing recurrence.

**Figure 1: The injury at the root of the penis of the first patient.**

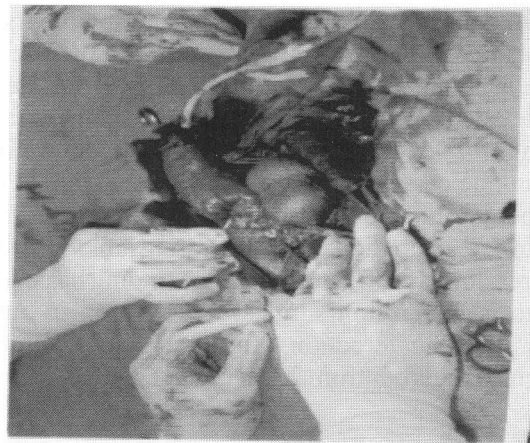


Figure 2: The deformed penis of the second patient with blood at the tip.

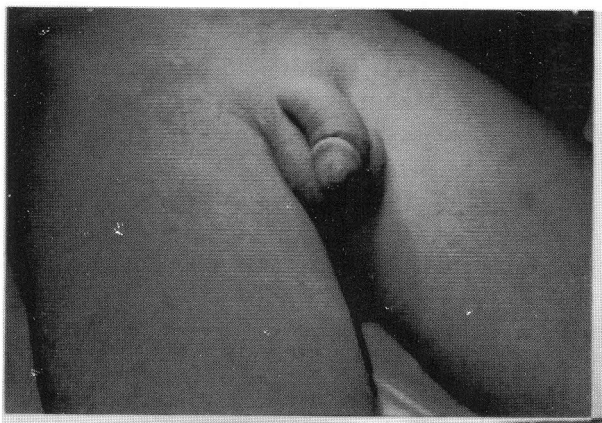
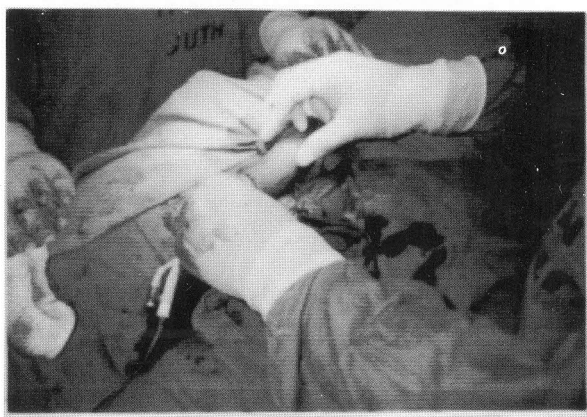
Figure 3: The Penis at the End of Surgery.



## DISCUSSION

Fracture of the penis occurs in every clime and affects all social strata. It is however commoner in countries where there is segregation of the sexes for religious and social reasons.<sup>10,11,12,13</sup> Majority of the patients are young sexually active men whose sexual function and virility could be threatened by this soft tissue 'fracture'. Vigorous masturbation and over enthusiastic consensual intercourse with a touch of athleticism and acrobatics are the predisposing factors for fracture of the penis. The two patients in this report are young, sustained the fracture during vigorous masturbation and consensual intercourse, and both of them were at the extremes of the social strata. The diagnosis was made obvious by the clear and detailed history of the patients and the clinical findings of tender penile swelling and deformity and, in one case, the presence of blood at the tip of the penis indicating associated urethral injury. Gentle deep palpation on the operating table showed a depression at the fracture site. The finding hastened diagnosis for prompt surgical intervention in both cases. During erection, the protective tunica albuginea thins out from 2 mm thickness to 0.25 mm.

After this elastic limit it snaps when direct blunt trauma is applied to it, thus exposing the rigid corpora cavernosa to trauma leading to rupture of the corpus cavernosum.<sup>1</sup> Vigorous masturbation and overenthusiastic consensual sex provide enough trauma to fracture the penis. The presence of blood at the tip of penis is indicative of urethral rupture in association with the corpus cavernosum tear. Urethral rupture commonly occurs in the reverse coitus position with the woman on top. This position fixes the urethra between the rigid corpora cavernosa and in this position the pelvic bone of the woman crushes the urethra during intercourse.<sup>8,10.</sup> The injury could vary from a minor tear as in the second patient to complete disruption of the urethra. Primary repair of the urethra is the choice of treatment in early presentation which leads to good voiding function.<sup>4,7,14</sup> This injury is uncommon with the man-above position during intercourse. Laubscher's subcoroner's sleeve (degloving) operation revealed the injuries in both patients. The disruptions in the corpus cavernosum were repaired transversely with 3-0 polyglactin (Vicryl) absorbable sutures to ensure leak-proof repairs. Injecting normal saline to the corpora cavernosa to achieve artificial tumescence helped to test the integrity of the repair. The ruptured deep dorsal vein of the penis in the first case was ligated with chromic sutures while the minor urethral tear was managed conservatively without stricture formation. The indwelling catheter served as a stent to reduce mobility and pain and hence facilitated healing under appropriate antibiotics. Conservative management with bed rest, ice packs, anti-inflammatory agents and fibrinolytics, sexual abstinence and estrogen to suppress erection had been reported to increase morbidity and lead to deformed penis and erectile dysfunction and infertility.<sup>17</sup> Counseling was effective in the second case in order to prevent refracture a complication noted by other workers when patients returned to the sexual practice that led to the fracture in the first instance<sup>7,22,24</sup>.

## REFERENCES

1. Karadeniz T, Topsakal M, Ariman A, Erton H, Basak D. Penile fracture: differential diagnosis, management and outcome. *Br J Urol* 1996;77:279-281.
2. Ruckle HC, Hadley HR, Lui PD. Fracture of penis: diagnosis and management. *Urology* 1992;40:33-35.
3. Jack GS, Garraway I, Reznichuk R, Rajfer J. Current treatment options for penile fractures. *Rev Urol* 2004;6:114-120.

4. **Jagodic K, Erklavec M, Bizjak I, Poteko S, Jagodic HK.** A case of penile fracture with complete urethral disruption during sexual intercourse: a case report. *J Med Case Reports* 2007;1:14.
5. **Ugwu BT, Yiltok SJ, Uba AF, Abdulmajid UF.** Fracture of the penis a rare injury on the Jos Plateau, Nigeria. *Cent Afr J Med* 1998;44:107-109.
6. **Mbonu OO, Aghaji AE.** 'Fracture' of the penis in Enugu, Nigeria. *J R Coll Surg Edinb* 1992;37:309-310.
7. **Llarena IR, Villafruela MA, Azurmendi AI, Garcia FJ, Pertusa PC.** Penile fracture with associated urethral rupture. *Arch Esp Urol* 2006;59:732-736.
8. **Wang CN, Hung CH, Ching CP, Chou YH, Wang CJ et al.** Recent experience of penile fracture (1989 -1993). *Kaohsiung J Med Sci* 1995;11:654-659.
9. **Shittu OB, Kamara TB.** Fracture of the penis diagnosis and management. *Afr J Med Med Sci* 2000;29:179-180.
10. **Eke N.** Fracture of the penis. *Br J Surg* 2002;89:555-565.
11. **Zargooshi J.** Penile fracture in Kermanshah, Iran: report of 172 cases. *J Urol* 2000;164:364-366.
12. **ElAbd S, Abu FO, El GM, El Sharaby M, El Mahrouky A.** Fracture of the penis and the result of surgical management. *Injury* 1988;19:381-383.
13. **El-Sherif AE, Dauleh M, Allowneh N, Vijayan P.** Management of fracture of the penis in Qatar. *Br J Urol* 1991;68:622-625.
14. **Kulovac B, Aganovic D, Junuzovic D, Prcic A, Hadziosmanovic O, Bazardzanovic M, Hodzic H.** Surgical treatment and complications of penile fractures. *Bosn J Basic Med Sci* 2007;7:37-39.
15. **Hinev A.** Fracture of the penis: treatment and complications. *Acta Med Okayama* 2000;54:211-216.
16. **Pliskow RJ, Ohme RK.** Corpus cavernosography in acute 'fracture' of the penis. *AJR Am J Roentgenol* 1979;133:331-332.
17. **Klein FA, Smith MJ, Miller N.** Penile fracture: diagnosis and management. *J Trauma* 1985;25:1090-1092.
18. **Blane D.** Inequality of Social Class. In : *Sociology as applied to Medicine*, Patrick DL, Scrambler G. eds. London, Philadelphia, Toronto. Bailliere Tindall 1982:114-124.
19. **Mohapatra TP, Kumar S.** Reverse coitus: mechanism of urethral injury in male partner. *J Urol* 1990;144:1467-1468.
20. **Pruthi RS, Petrus CD, Nidess R, Venable DD.** Penile fracture of the proximal corporeal body. *J Urol* 2000;164:447-448.
21. **Laubscher WM.** Fraktur van die penis. *S Afr Med J* 1972;46:1044.
22. **Ruckle HC, Hadley HG, Luy PD.** Fracture of penis: diagnosis and management. *Urol* 1992;40:33-35.
23. **Meares EM Jr.** Traumatic rupture of the corpus cavernosum. *J Urol* 1971;105:407-408.
24. **Singh RB, Copal M, Dahiya RS.** Recurrent ipsilateral fracture of the penis. *Injury* 1995;26:575.