



Original article

Renal damage with Cotecxin and Chloroquine than with Amalar and Fansidar

JIMMY E. O^{1,*}, USOH, F ETIM^{1,2}, O. E³,EKWERE E. O.⁴

Author Affiliations

¹Department of Physiology,
Faculty of Basic Medical Sciences, University of Uyo,
Akwa Ibom State, Nigeria

^{2&3}Department of Biochemistry,
Faculty of Basic Medical Sciences, University Of Uyo,
Akwa Ibom State, Nigeria.

⁴Department of anatomy, Faculty of Medical Sciences,
University of JOS, Nigeria.

Author's contribution:- Both the author contributed equally to this paper.

Corresponding Author

JIMMY, E. O.
Department of Physiology
Faculty of Basic Medical Sciences,
University of Uyo, Akwa Ibom State, Nigeria

Abstract

Antimalaria drugs; chloroquine, fansidar, cotecxin and amalar were administered on thirty albino rats to observe their effects on the kidney for 28 days. In the chloroquine group there was marked

infiltration of the inflammatory cells in the interstitial space of the medulla. There was also the dilation of the bowman's space and loss of brush borders of the epithelial cells. In the fansidar group, normal renal capsule with few inflammatory cells were observed and the proximal and distal convoluted tubules were moderately distorted. However, the bowman's epithelium was not affected. In the amalar group there was marked enlargement of the glomerulus in the bowman's space but without any associated corpuscular increase in size and the medulla was not affected. There was diffused neutrophilic infiltration in the renal cortex and mild dilation of the interstitial spaces and necrosis of the glomerulus and renal capsule infiltration with inflammatory cells in cotecxin group. It is shown in the study that continuous intake of chloroquine and cotecxin may lead to kidney disease.

Key words: Kidney; renal damage; cotecxin; chloroquine; amalar and fansidar.

INTRODUCTION

The kidney is a paired bean shape organ situated in the posterior abdominal cavity.

It contains about a million nephrons; the functional units capable of forming urine each consisting of glomerulus with proximal tubule, loop of henle and distal convoluted tubule which drains to the collecting duct.

The major function of the kidney is the formation of urine and by this the kidney clears undesirable toxic metabolic substances from the body and aids the reabsorption of the electrolytes by the body. In kidney failure these functions are halted which may lead to death. However, other functions like regulation of acid-base balance, secretion, metabolism, excretion of hormones and glucoseneogenesis are also performed by the kidney¹.

Generally every drug is likely to have side effect(s) on any organ in the body but the relationship of such effects on the half-life of the drug, the disease

prevalence, drug usage and duration of exposure need be clinically addressed. For instance, malaria is a permanent disease in our environment and so antimalaria drugs are invariably permanently used. There is therefore the tendency to have permanently induced organ disease. For example malaria affects all organs in the body⁸ and renal failure and myositis are reported in malaria⁷. Continuous evaluation of organ damage possibility in all antimalaria drugs administration is very desirable due to their increase utilization in malaria treatment. Nephrotoxicity may likely correlate high patronage of these drug as per their cheapness and availability e.g. chloroquine and fansidar.

Moreso, the new antimalaria drugs, cotecxin ® and amalar ® are already experiencing high utilization with the tendency of corresponding organ(s) damage. The study therefore considered the option of the likely organ damage with

increase self medication⁴ and decided to compare kidney damage with the old antimalaria drugs; chloroquine and fansidar and the new ones; cotecxin and amalar as advisory approach for the treatment of malaria disease.

MATERIALS AND METHODS

A total of thirty (30) rats weighing 80–166g at average were used for the study. The animals were fed with pellet food and water in the animal house of the Pharmacy Faculty, University of Uyo. The animals were divided into four drug groups; chloroquine, fansidar, amalar and cotecxin including control and six animals were assigned randomly to each study group.

DRUG PREPARATION AND ADMINISTRATION

Four drugs were used in the study; chloroquine®, fansidar®, amalar® and cotecxin®. The drugs were prepared based on the average weight of man, 70kg and weights of the animals and according to methods of (Bertram, 2004 and Robert 1979)^{2,6}. For chloroquine 4 tablets of 250mg was given for the first day, the same dosage for the 2nd day but 2 tablets in the third day. The tablets were ground and dissolved in 100ml of distilled water and given orally to the animals using metallic canula-by-passing the oesophagus into the stomach. For fansidar, 3 tablets of 525mg were ground and dissolved in 100ml and given 1mg/ml to the animal as single dosage, the same preparation was adopted for amalar. Sixty (60mg) of cotecxin was dissolved in 100ml of distilled water and given 1mg/ml for seven days. The drugs were purchased in a registered Pharmacy shop in Uyo Akwa Ibom State Nigeria where the study was done. The effects of the drugs were observed weekly for 28 days according to WHO(1982)⁹, drug monitoring effects on malaria parasites development and cure rate. This was adopted for the study though malaria parasites were not given to the animals but was meant to observe the effects of the drugs using same schedule. At the end of each week – (7 days) interval some animals in each group were sacrificed after chloroform anesthesia and the kidneys were removed and stored in 10% formalin solution for histological analysis. This was done for the period of 28 days.

KIDNEY PROCESSING AND PREPARATION

The method of Druby and Wallington 1967³ was used in the processing of the kidney. But briefly, the kidney was fixed in 10% formalin after collection from the animals to maintain the cells in the normal microanatomical positions particularly to prevent it from degeneration. The kidneys were prepared for clearing by removing the fixative and any water by dissolving in ascending grades of

alcohol; 50%, 70%, 95% and 100% for two hours each. The alcohol was cleared by fixing the kidneys in pure xylene to make the organ transparent. The cleared kidneys were impregnated in molten paraffin wax and maintained at the temperature between 54°C – 60°C to avoid burning of the tissue in the oven. The impregnation enhanced the removal of zylene and the permeation of the paraffin wax. The kidneys were embedded in fresh molten paraffin wax and allowed to solidify. The aim being to obtain a solid block containing mould with some molted paraffin wax. The paraffin blocks from the mould were trimmed to remove excess paraffin wax with a bench knife. The trimmed wax with the organ was mounted on a wooden block by slightly melting it with a hot spatula and labelled. The blocks were later fixed in the microtome and trimmed to expose the tissues in the kidney organ. The block of tissues were then cut in thin sections of 3cm in thickness, and spread on slides with the aid of paraffin ribbons. The best sections were floated on a glass slide smeared with Mayer's glycerol albumin to help to adhere the sections of the cut organ on the slide. The slides were then firmly placed in a wooden tray in an inclined position and dried at 60°C for 24 hours in incubator for the purpose of dewaxing the sectioning. After dewaxing, the slides were washed under running tap water for 10 minutes. With the use of haematoxylin stain the slides were stained for 15 minutes. The sections were differentiated with 1% acid alcohol for 1 minute by constant agitation after removal of excess haematoxylin by washing the slides with water for 2 minutes. The slides were counter stained with eosin for 5 minutes and rinsed with water for 1 minute. The slides were then transferred into graded alcohol, first with 95% ethanol, once for 2 minutes, then in 100% ethanol twice for 5 minutes. The stained slides were again rendered transparent in xylene to rid off alcohol for 2 minutes. The slides were blotted with filter paper and covered with cover slip using DPX mounting and left to dry. The tissues in the slides were viewed under the light microscope for any micro anatomical changes in comparison with the control. Photomicrographs were then taken for clarity.

RESULTS

The results showed marked infiltration of the inflammatory cells in the interstitial space of the medulla with dilation of the bowman's space and loss of brush borders of the epithelium in rats administered with chloroquine, (plate 1) such anomalies were not found in rats without chloroquine which served as control, (plate 2). In the group with fansidar administration normal

renal capsule with few inflammatory cells were observed but the proximal and distal convoluted tubules were moderately distorted, (plate 3) whereas such were not found in the control group (plate 2). There was marked enlargement of the glomerulus in the bowman's space in rats administered with amalar drug but without any associated effect on the medulla, (plate 4).

However, in cotecxin drug group there was diffused neutrophilic infiltration in the renal cortex and mild dilation of the interstitial spaces not seen in the control, (plate 5). There was also the necrosis of glomerulus and renal capsule was infiltrated with inflammatory cell.

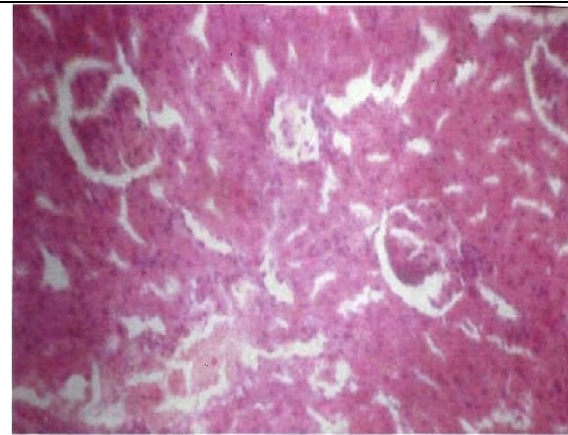


Plate 1 Chloroquine effects on kidney

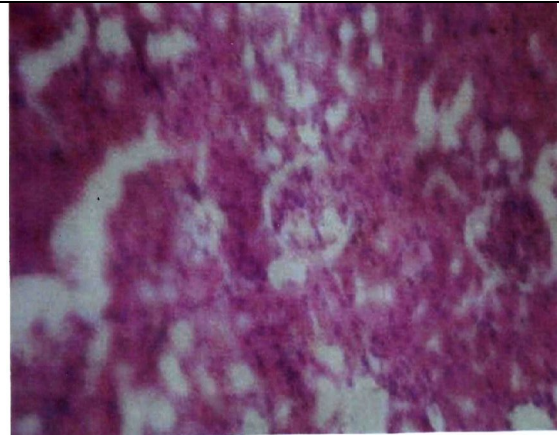


Plate 2 Control

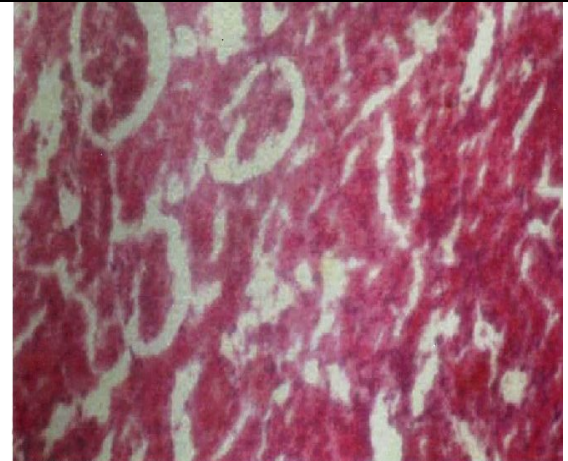

Plate 3 Fansidar effects on kidney

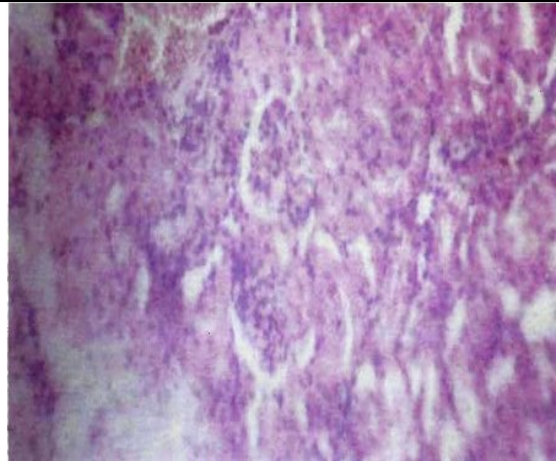


Plate 4 Amalar effects on kidney

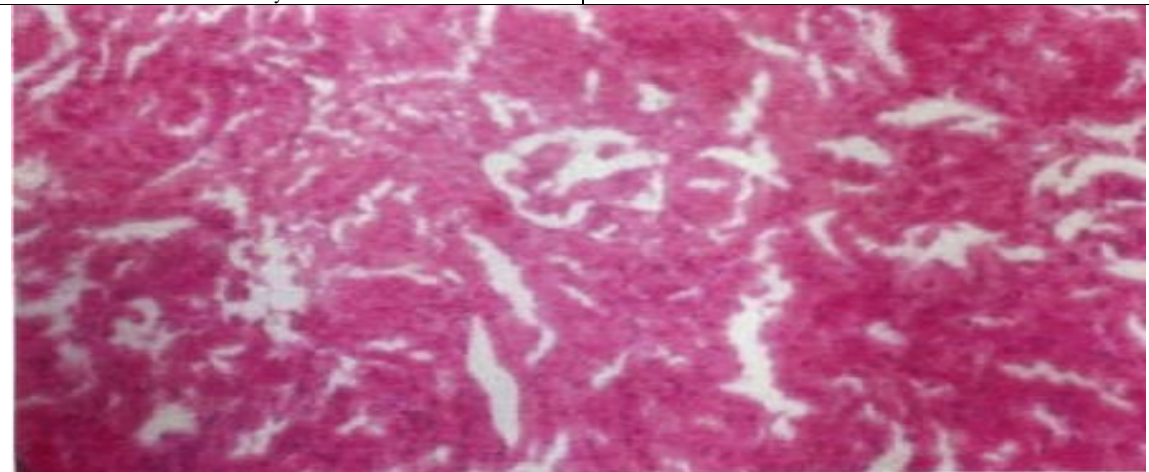


Plate 4 Cotecxin effects on kidney

DISCUSSION

The study has unveiled significant observations with various antimalaria drugs used and the effects on the kidney. For instance, each antimalaria drug has specificity in reaction with different components of the kidney. For example chloroquine is observed in the study to have caused dilation of the bowman capsule, inflammation of the medulla and loss of brush border of the epithelium. On the other hand, fansidar only distorted the proximal and convoluted tubules whereas amalar caused the enlargement of the glomerulus. But cotecxin administration led to necrosis of the same glomerulus and inflammation of the renal capsule in the animals studied. On weighted effects none of these anomalies no matter how mild is to be taken less seriously as cumulation of such effects would lead to unpleasant consequences as far as the body physiology is concerned. However, the cotecxin and chloroquine effects are seriously viewed as both are curative drugs. Chloroquine is found to induce changes in serum and kidney enzymes resulting in primary renal dysfunction and other pathologic effects⁵. This further confirms the anomalies on kidney effected by chloroquine in our study and particularly the inflammatory effects of chloroquine which suggest pyelonephritis and glomerulonephritis conditions. These histologic aberrations by chloroquine are significant due to the place of this drug in the chemotherapy of malaria as the cheapest and most available of all the antimalaria drugs. However,

such impact by the new drug; cotecxin is taken most seriously as is meant to be alternative drug to chloroquine due to chloroquine resistant strain; Plasmodium falciparum. It is too early for cotecxin to cause necrosis of the nephron component (glomerulus), suggesting that the drug may likely be a candidate of renal failure even as amalar is marking time for the same activity through its enlargement effect on the glomerulus. Incidentally the two new drugs seem to be targeting nephrons the same pathway by malaria disease⁷. This is very dangerous and the trend need by checked by continuous monitoring of antimalaria drugs on organs particularly these days of rebranded versions of old drugs with new names. It is observed that both fansidar and amalar had mild affects on the kidney which may be attributed to the drugs being given as protective. This explains the dosage, concentration, half-life effects of the drugs compared with cotecxin and chloroquine. But the mildness of the fansidar and amalar drugs need not be celebrated as cumulative mildness will eventually result in renal damage. Moreso, these drugs are ignorantly taken by many as curative particularly in clinical and parasitological failures in malaria disease. There is need for policy guidelines on the distribution of new drugs which first, should meet safe standard under longer duration of utilization. And health agencies should implement this to forestall likely population maiming even as malaria is taking exterminating posture.

REFERENCES

1. Bell G. H. Bell, D. E. Smith & C. R. Paterson (1980): In textbook of physiology, Tenth edition, Longman Group Edinburgh.
2. Bertram G. (2004): In Basic Clinical Pharmacology, 9th edition, New York, Chicago, Sanfrancisco, London.
3. Druby, R. A. B. & Wallington (1967); In Histological Technique Fourth Edition, Oxford University Press New York.
4. Jimmy, E. O., Achelonu, E. & Orji, S. (2000). Antimalarials dispensing pattern by patent medicine dealers in rural settlements in Nigeria. Public Health Journal, England, 114, 282-285.
5. Ngaha, E. O. Akanji, M. A. Madusolumuo, M. A. (1989). Studies on correlation between chloquine induced tissue damage and serum enzyme changes in rat. Journal of cellular and molecular life science, 45:2, 143-146.
6. Robert, A. (1979). Gastric Cytoprotective property of prostaglandin. Gastroenterol. 77:762-769.
7. Sinniah, R., & Lye, W. C. (2000). Acute, Renal Failure from Myoglobinuria secondary to Myositis from severe falciparum malaria. American Journal of Nephrology, 20:4, 1-2.
8. Vuong, P. N. Richard F., Sinounou G. Coquelin. F. Renza L., Gonnet F., Chanaud, A. & Landau L. (1999). Development of irreversible lesions in the brain, heart and kidney following acute chronic murine malaria infection. Cambridge Journals, 119:543-553.
9. WHO (1982): In modern design of antimalaria drugs. Proceedings of a meeting held in Bethesida, Maryland USA.

Conflict of interest :- Author has not declared any conflict of interest.

Source of funding :-None