

# SPONTANEOUS RESOLUTION OF COMPLETE ATRIOVENTRICULAR (A-V) DISASSOCIATION IN AN ELDERLY WOMAN- A CASE REPORT

C. M. Chundusu, V.S.Gomerep, Y. Kumtap

Department of Medicine, Jos University Teaching Hospital,  
PMB 2067. Jos, Nigeria

*All correspondence to: Dr Caleb Chundusu,*

*University of Jos/Jos University Teaching Hospital. PMB 2067 Jos, Nigeria*

*Phone: 08037032797*

*Email: calebchundusu@yahoo.com*

## **Abstract**

*Atrioventricular (A-V) disassociation describes the independent beating of the atria and ventricles of the heart. It is not synonymous with complete heart block in the sense that, A-V disassociation is a general term. Heart block describes specific conduction abnormalities that need specific cardiac intervention. This case report highlights the development of an A-V disassociation, which resembled a heart block, as an unusual complication of sepsis in an elderly woman.*

## **Introduction**

The major reversible cause of conduction system disturbances are high vagal tone and medications, most of which are not usually accompanied by presyncope or syncope and require no treatment [1]. A variety of viral, bacterial and parasitic aetiologies of myocarditis result in varying degrees of A-V disassociation. These include: Lyme disease, rheumatic fever, Chagas's disease [3], tuberculosis, measles, and mumps. Transient AV block is the most frequently seen cardiac abnormality associated with Lyme disease. First-degree block is almost always observed in these cases, representing up to 8% of those infected [3]. Complete heart block can develop in 50% of those with first-degree block, especially if the PR interval exceeds 0.30 seconds [4,5]. Acute rheumatic fever almost invariably results in PR prolongation when carditis is present. [6,7] Second-degree block occurs only occasionally and progression to complete heart block is rare [8]. Complete heart block occurs in 3% of cases of infective endocarditis, with the

aortic valve being involved more frequently than the mitral valve [1,2].

The clinical presentation of septicaemia may not be so obvious in the elderly, who may initially display new-onset or worsening confusion and few other manifestations. What remains unclear is that could these other manifestations include A-V disassociation?

## **Case Report**

A.D. is a 94-year-old woman who was referred by the family physician when she was noticed to be weak with poor appetite and had a very slow pulse.

On examination she was found to be lethargic, restless and warm (temperature = 36.4°C). On chest examination, she had coarse crepitations on the left mid and lower lung zones posteriorly. Pulse was 44 beats per minute, blood pressure was 90/60 mmHg, jugular venous pulse was not visible, apex was not displaced and heart sound were normal.

Investigations showed complete heart block

on electrocardiogram [Figure 1], non-homogeneous opacity on the left middle and lower zones on chest x-ray and echocardiography showed diastolic dysfunction in a structurally normal heart. Full blood count and differential tests were unremarkable: packed cell volume was 34%, erythrocyte sedimentation rate was 10mm/hr, total white cell count 7,800/mm<sup>3</sup> (neutrophils = 67%, lymphocytes = 25%, eosinophils = 2%, monocyte = 0% and basophils=0%).

Treatment was commenced with 2g of ceftriaxone given intravenously daily and azithromycin tablets 250mg twice daily given for 3 days. Patient's relatives declined admission however they were counselled on the possibility of the patient having a pacemaker/intracardiac defibrillator inserted in her. Two days later, patient had become very active and eating voraciously. Vital signs had improved and the pulse rate rose up to 78 beats per minute. Repeat ECG reveal normal sinus rhythm [Figure 2]. When seen two weeks later at the medical outpatient department, ECG remained normal.

## DISCUSSION

Elderly patients presenting with multi-organ disorders usually present a unique challenge to the attending physician, particularly in an environment like ours, where geriatric medicine is still at a rudimentary phase of development. Pneumonia in the elderly is a severe disease because of their relatively low immunity and susceptibility to a wider range of organisms. Its presentation poses a great challenge because of the different ways it manifests in the elderly. Complete heart block appears to be one of the ways it can manifest going by the nature of this case report.

Our patient had significant bradycardia without obvious evidence of a structural heart abnormality. She was neither hypertensive nor was there any history

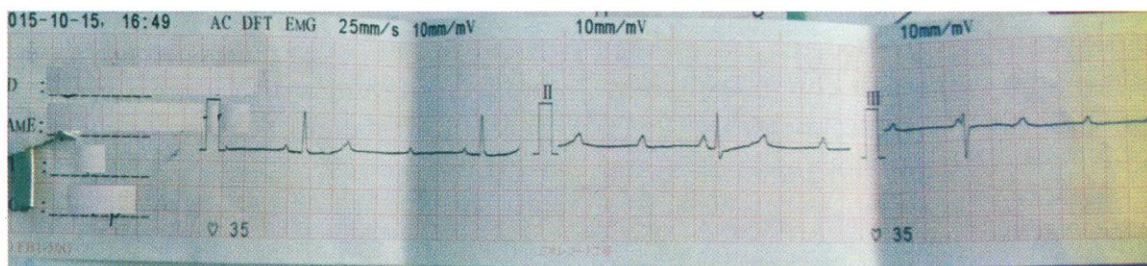
suggesting heart disease. She however had an electrocardiogram (ECG) suggestive of a complete heart block. The presence of an electrophysiologic study would have gone a long way in specifically identifying a block and the site of the block. A-V disassociation was considered in this elderly patient because of symptoms associated with bradycardia and an ECG showing a complete heart block pattern that resolved completely with antibiotics. Complete heart block is mostly due to structural damage of the conducting system of the heart that would likely require some specific cardiac intervention (intra-cardiac device insertion to be precise). Although most A-V disassociations have faster atrial rates, it is not invariable and complete heart block is a form of A-V disassociation.

Although the aetiology of the community acquired pneumonia was not firmly established, it is possible that a microbe was responsible for the A-V disassociation. Resolution of chest signs and improvement in pulse rate on antibiotics gives credence to our assertion.

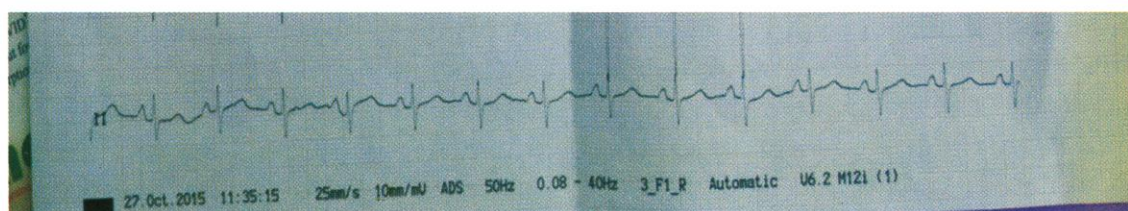
A less-frequent or a rare manifestation of reactive arthritis (Reiter's syndrome) is cardiac conduction defects, including complete heart block. However the triad of arthritis, urethritis, and conjunctivitis representing part of the spectrum of the clinical manifestations of Reiter's syndrome was not seen. This syndrome is associated with HLA-B27. In most hospital-based series in which *Shigella*, *Yersinia*, or *Chlamydia* were the triggering infectious agents, 60–85% of patients were found to be HLA-B27 positive; with *Salmonella* and *Campylobacter*, it is lower [9]. In more recent community-based studies, the prevalence of HLA-B27 has often been below 50%, and in some instances not elevated at all [9]. Antibiotic is used for treatment of Reiter syndrome but most times to prevent complications.

Our search for a logical explanation of what happened in this case report still remains speculative, however, we suggest that in patients, especially the elderly with an ECG suggesting complete heart block, curable

causes should be investigated for before considering interventions that are expensive and non-existent in our environment.



**ECG of patient before treatment.**



**ECG of patient after treatment**

## References

1. Wang K, Gobel F, Gleason DF, et al. Complete heart block complicating bacterial endocarditis. *Circulation* 1972;46:939–947.
2. DiNubile MJ, Calderwood SB, Steinhaus DM, et al. Cardiac conduction abnormalities complicating native valve active infective endocarditis. *Am J Cardiol* 1986;58:1213–1217.
3. Hagar JM, Rahimtoola SH. Chagas' heart disease in the United States. *N Engl J Med* 1991;325:763–768.
4. Steere AC, Batsford WP, Weinberg M, et al. Lyme carditis: cardiac abnormalities in Lyme disease. *Ann Intern Med* 1980;93:8–16.
5. Van der Linde MR, Crijns HJ, de Koning J, et al. Range of atrioventricular conduction disturbances in Lyme borreliosis: a report of four cases and review of other published reports. *Br Heart J* 1990;63:162–168.
6. Bland EF, Jones TD. Rheumatic fever and rheumatic heart disease. A twenty year report on 1000 patients followed since childhood. *Circulation* 1951;4:836–843.
7. Mirowski M, Rosenstein BJ, Marbowitz M. A comparison of atrioventricular conduction in normal children and in patients with rheumatic fever, glomerulonephritis, and acute febrile illnesses. *Pediatrics* 1964;33:334–340.
8. Wood P. *Diseases of the heart and circulation*, 3rd ed. Philadelphia: Lippincott, 1968:588.