

Contents lists available at Sjournals



Journal homepage: www.Sjournals.com



Original article

Some comparative gross and morphometrical studies on the gastrointestinal tract in pigeon (*Columba livia*) and Japanese quail (*Coturnix japonica*)

S.A. Hena*, M.L. Sonfada, A. Danmaigoro, A. Bello, A.A. Umar

Department of Veterinary Anatomy, Faculty of Veterinary Medicine, Usmanu Danfodiyo University, Sokoto, Nigeria.

*Corresponding author; Department of Veterinary Anatomy, Faculty of Veterinary Medicine, Usmanu Danfodiyo University, Sokoto, Nigeria; Tel.: +2348060524623

ARTICLE INFO

ABSTRACT

Article history:

Received 18 August 2012

Accepted 25 August 2012

Available online 28 August 2012

Keywords:

Comparative

Gastrointestinal tract

Pigeon

Quail

To study the comparative morphology and morphometry of the gastrointestinal tract of the Japanese quail and pigeon, a total number of twenty birds (comprising of ten pigeons and ten Japanese quails) of both sexes were used obtained and used by the researchers. The birds were weighed, dissected and the different parts of the gastrointestinal tract located and eviscerated from which the comparative morphologic and morphometric studies were carried out. The numerical data generated were subjected to statistical analyses using the Microsoft Office Excel 2007 and GraphPad InStat statistical package, with values of $P < 0.05$ considered significant. The weights of esophagus in quail and pigeon were $1.66 \pm 0.15\text{g}$ and $1.62 \pm 0.2\text{g}$ respectively ($P > 0.05$), their corresponding lengths were $9.77 \pm 0.35\text{cm}$ and $12.46 \pm 0.99\text{cm}$ respectively, while the mean body weights of the quail and pigeon used in the study were $159.5 \pm 8.18\text{g}$ and $265 \pm 4.86\text{g}$ for the quail and pigeon, respectively ($P > 0.05$). The mean weights of the proventriculus in the quail and pigeon were $0.69 \pm 0.07\text{g}$ and $0.54 \pm 0.09\text{g}$ respectively ($P > 0.05$) and their mean lengths were $1.75 \pm 0.13\text{cm}$ and $1.44 \pm 0.28\text{cm}$ respectively; this was not considered significant relative terms. The weights and lengths of gizzard in the quail and pigeon showed different values with the ultimate conclusion that the gizzard's weight and length were higher in the pigeon than in the quail ($P < 0.05$). It was also seen

in both absolute and relative terms that the lengths and weights of the small intestines in the pigeon were higher than that of the quail though with no considerable significant differences ($P>0.05$). The ceca in the pigeon was rudimentary in contrast to the robust type found in the quail, the weights of both the right and left ceca in the quail and pigeon were considered very significant ($P<0.05$) and their corresponding lengths considered extremely significant ($P<0.05$). The colon, being the terminal part of the large intestine is located caudal to the ceca, had their weights in both quail and pigeon not significantly different statistically, but in absolute and relative terms they differed from each other similarly the lengths of the colon in both bird types were considered significant ($P<0.05$). The vertebrate gastrointestinal tract is a dynamic and energetically expensive organ system whose various anatomical and physiological parameters were regularly being used in clinical evaluations and for assessing dynamics of growth and associated physiological functions for normal and anomalous developments in birds, the knowledge of which will not only add to literatures in these bird types but which will also aid in understanding their biology and mode of domestication as well as being useful for poultry pathologists and clinician, more especially when carrying out postmortem examination.

© 2012 Sjournals. All rights reserved.

1. Introduction

The pigeon (*Columbia livia*) is one of the commonest birds kept and bred by amateurs as ornamental birds, messenger and for meat purpose and a member of the bird family *Columbidae* (doves and pigeons) (Gibbs et al., 2007). They originally originated from Europe, and at present widely distributed all over the world. During the eighteenth and nineteenth centuries, feral pigeons were spread intentionally and/or accidentally by travelers (Johnston and Janiga, 1995). They are robust, resistant to disease and easy to keep requiring only simple cage and equipment and little space and can be kept on free range. Pigeon production is cheap as the pigeons are mostly kept on free range with only small boxes or houses, which accommodate them and requires less capital outlays in terms of housing, management and health care (Omojola et al., 2012; Kigir et al., 2010).

The Japanese quail is a small avian species kept for meat and egg production (Minvielle, 1998; Baumgartner, 1994). It is widely being used as a model in research in a variety of disciplines including physiology, nutrition, endocrinology, pathology, embryology, reproduction and immunology. Physiological and anatomical parameters serve as valuable tools for predicting outcome consequences (Tilgar et al., 2008; Vatsalya and Arora, 2011).

Some reports have been published on the morphology and morphometry of the small intestine of some species of birds (Casotti, 2001; Lavin et al., 2008; Igwebuike and Eze, 2010; Wang and Peng, 2008; Mobini, 2011), but there is a paucity of information on the morphology of the digestive tract of the Japanese quail and pigeon. It is known that environmental diversification of the habitat of birds and their consecutive ways of nourishment, as well as the sorts of food they feed on constitute a source of great variety in the structure of their digestive tract (Dziala-Szczepanczyk and Wesolowska, 2008), the vertebrate gastrointestinal tract is a dynamic and energetically expensive organ system (Brugger, 1991), though the digestive system in the domestic fowl is very simple but efficient when compared to many other species like cattle, it need needs to be studied. Thus, this study aims at evaluating the morphologic and morphometric gastrointestinal tracts of the quail and pigeon, the knowledge of which will not only add to literatures in these bird types but would also aid in understanding their biology and mode of domestication, as well as finding application in poultry medicine and to poultry pathologists.

2. Materials and methods

Twenty birds (ten pigeons and ten Japanese quails) of both sexes were purchased from a poultry market in Sokoto metropolis, Sokoto-Nigeria, were used in this study. Immediately after purchase, the birds were caged in well ventilated cages and transported by road to the Department of Veterinary Anatomy, Faculty of Veterinary Medicine, Usmanu Danfodiyo University, Sokoto. The birds were sedated lightly using chloroform as inhalant anaesthetic. The body weight (live weight) of each bird was obtained with a Digital Electronic balance (CITIZEN SCALES 1 PVT. LTD, Model MP-600, with a sensitivity of 0.01g). The birds were then euthanized by an overdose of chloroform soaked on cotton wool with each bird put in an enclosed container. With the birds on dorsal recumbency an incision was made caudo-cranially from the vent to the shoulder joint on the lateral surface, the keel bone and associated muscles were reflected to the opposite side thereby giving access to the viscera. The location of the esophagus, crop (where present, because some were ruptured in the course of the dissection), proventriculus, gizzard, small intestine, ceca and colon were studied in-situ, then exteriorized and snapped using a digital camera (Samsung, ES10, 8.1 MEGA PIXELS) and their individual lengths determined using a thread which was stretched against the length of the organ to be measured from where the length of the thread was being matched to a ruler which was graduated in centimetre. The weights of these structures were also obtained in grams using a sensitive Digital Electronic balance (CITIZEN SCALES 1 PVT. LTD, Model MP-600, with a sensitivity of 0.01g). The weights of the ceca in pigeon could not be measured due to their insignificant weights, as the ceca were rudimentary in this bird type.

The data generated were subjected to statistical analyses using the Microsoft Office Excel 2007 and GraphPad InStat statistical package, with values of $P < 0.05$ considered significant.

3. Results and discussion

3.1. Esophagus and crop

From this study the esophagus of both the quail and pigeon were observed to be thin-walled distensible tube which extended from the pharynx to the gizzard and lies dorsal to the trachea. The esophagus of the quail and pigeon, just like in other birds, had three distinct portions: cervical part, crop and thoracic part, though in this study the crop was not thoroughly studied as most got ruptured in the course of the dissection. The cervical part of the esophagus was considerably larger than the thoracic part, this finding agreed with the works of Parchami and Dehkordi, (2011) in quail. Inside the thoracic cavity, the oesophagus enters or becomes the proventriculus – a very glandular part of the digestive tract, often called the glandular stomach.

The weight of esophagus in quail and pigeon were $1.66 \pm 0.15\text{g}$ and $1.62 \pm 0.2\text{g}$ respectively, these were not considered significant ($P > 0.05$), their lengths were $9.77 \pm 0.35\text{cm}$ and $12.46 \pm 0.99\text{cm}$ for the quail and pigeon respectively (Tables 1 and 2). The mean body weights of the quail and the pigeon used in the study were $159.5 \pm 8.18\text{g}$ and $265 \pm 4.86\text{g}$ respectively, though not statistically significant ($P > 0.05$). According to Brugger, (1991), the size of digestive organs can be greatest during times of the year when intake is high, possibly due to low available energy food, rapid processing rates, or high metabolic demand. However, in this study time of the year was not a considered factor. The morphology of the digestive tract of a given animal species is related to the nature of food, feeding habits, body size and shape (Smith, 1989).

Both bird types have crops though they were not studied in details in this work due to their rupturing at dissection. The crop was found as a dilatation of the esophagus before the proventriculus. It was apparent in this study that the crop of the pigeon is well developed than that of the quail (Plates 1 and 2). This variation is probably consequent upon the fact that the pigeon is known to produce 'crop milk' for feeding their young ones during the first two weeks after hatching (Pesek, 1999). The crop provides the capacity to hold food for some time before further digestion commences. This capacity enables the bird to take its food as "meals" at time intervals but permits continuous digestion.

3.2. Stomach

Birds have two part stomach, a glandular portion known as the proventriculus and a muscular portion known as the ventriculus or gizzard; gizzard has thick muscles (Pesek, 1999). In agreement to the work of Ahmed et al., (2011) in quail, the glandular portion (proventriculus, *Ventricular glandularis* or the true stomach) in this study,

was found to be located caudal to the esophagus, and the gizzard (*Ventricular muscularis*) was located caudal to the proventriculus, and were spindle in shape (Plates 1 and 2). The mean weights of the proventriculus in the quail and pigeon were $0.69\pm 0.07\text{g}$ and $0.54\pm 0.09\text{g}$ respectively ($P>0.05$). Similarly their mean lengths were $1.75\pm 0.13\text{cm}$ and $1.44\pm 0.28\text{cm}$ respectively; this was also not considered significant relative terms. According to Degen et al., (1994), the proventriculus varies in size between different species, and that in graminivorous it is of smaller size than in carnivores where the proventriculus is larger and more distensible, in this study however, both of the bird types used were graminivores and however no comparison was made with the proventriculus of carnivorous birds, but apparently the proventriculus observed in this study were all small.

In both the quail and pigeon, the muscular stomach or gizzard was seen as a spheroidal organ located immediately caudal to the proventriculus and placed partly between the lobes and partly behind the left lobe of the liver. It has a flattened, rounded shape somewhat like a convex lens, with one side slightly larger than the other. Each surface is covered by a glistening layer of tendinous tissue – thicker at the centre and becoming thinner towards the edges. These were in agreement with the reports of Pesek, (1999).

From Tables 1 and 2, the weight and length of gizzard in the quail were $4.06\pm 0.22\text{g}$ and $2.38\pm 0.20\text{cm}$ with percentage relative weight of 31.6% and relative length of 2.54%. While, the pigeon had their weight and length of the gizzard as $6.86\pm 0.69\text{g}$ and $2.75\pm 0.25\text{cm}$ and their relative percentage gizzard weight and length as 45.3% and 3.2%, respectively. It thus showed that the gizzard weight and length were higher in the pigeon than in the quail. This finding agreed with the work of Ahmed et al., (2011) which confirm the quail to possess small gizzard.

3.3. Intestines

Plates 1 and 2 showed the GIT of both the quail and pigeon, indicating the small intestine to have began at the exit from the gizzard and ended at the junction of the small intestine, ceca and colon. The small intestine which consisted of duodenum, jejunum and ileum, is relatively simple and short but highly efficient nevertheless (Dibner and Richards, 2004) but however, in this work no distinction was made between the different small intestinal segments but they were simply classified and studied as the 'small intestines'.

Tables 1 and 2 showed the mean weight and length of the small intestine in the quail as $4.56\pm 0.36\text{g}$ and $55.6\pm 2.68\text{cm}$ respectively, while their relative percentage weight and percentage length were 35.5% and 59.4% respectively. The pigeon had their mean weight and length of the small intestines as $5.73\pm 0.04\text{g}$ and $65.12\pm 4.02\text{cm}$ respectively, while their relative percentage weight and percentage length as 37.9% and 76.8% respectively. This finding is in contrast to the findings of Brugger, (1991) who found out that the total small intestinal length was between 20.1 to 21.4 cm in the red winged blackbird; though the bird types used were not the same but they all belongs to the same family of avian.

It could be seen in both absolute and relative terms that the lengths and weights of the small intestines in the pigeon were higher than that of the quail, though with no considerable significant differences ($P>0.05$). It is relatively long and has a constant diameter. Of the three parts of the mammalian small intestine – the duodenum, jejunum and ileum, only the duodenum can be easily distinguished in the fowl. There are no clear demarcation between the jejunum and ileum and the small intestine appeared as one long tube.

The digestive tract of most birds contains a pair of outpocketings that project from the proximal colon at its junction with the small intestine, these ceca are usually fingerlike in shape, looking much like simple lateral extensions of the intestine, but some are complex in structure (Clench and Mathias, 1995). The large intestine consisted of paired ceca and colon or rectum and is actually shorter than the small intestine (Getty, 1975). Both intestines are characterised by a great morphometrical and functional variability, both between and within species (Mobini, 2011). The ceca of the quail are very prominent and longer than that in the pigeon (Plates 1-4), clearer distinctive views are seen on Plates 3 and 4, where in contrast to the long ceca of the quail, a rudimentary structure, the ceca, are found in the pigeon. The ceca are found immediately caudal to the ileum and cranial to the colon, these three intestinal segments meet at the ileo-ceco-colic junction in both quail and pigeon.

The right and left cecal weights and lengths in the quail were $0.53\pm 0.10\text{g}$ and $0.53\pm 0.11\text{g}$ for the weight; $8.13\pm 0.26\text{cm}$ and $8.13\pm 0.26\text{cm}$ for the lengths respectively. In the pigeon, the right and left cecal lengths were recorded as $0.36\pm 0.05\text{cm}$ and $0.38\pm 0.06\text{cm}$ respectively. The weights of the ceca could not be obtained due to their insignificant values as they measure below the sensitivity of the electronic balance use (i.e 0.01g). The weights of both the right and left ceca in the quail and pigeon were considered very significant ($P<0.05$) and their corresponding lengths considered extremely significant ($P<0.05$). In his works on red-winged blackbirds, Brugger (1989; 1991) found out the bird had small ceca with a total combined cecal lengths of between 0.45 to 0.5cm;

similar finding in this study was that the length of the combined right and left ceca was 0.74cm in the pigeon, confirming that the ceca is also small in the pigeon. Mobini, (2011), in his work on broiler, found out that the combined cecal lengths ranged between 2.22 to 10.83cm; the finding in our research revealed the combined cecal length in the quail to be 16.26 cm and that of pigeon put at 0.74cm, thus these our findings is in contrast with the reports of Mobini (2011), though his work was on broilers.

The avian cecum is a multi-purpose organ, with the potential to act in many different ways-and depending on the species involved, its cecal morphology, and ecological conditions, cecal functioning can be efficient and vitally important to a bird's physiology, especially during periods of stress. Many familiar avian species, such as chickens and ducks, have very large ceca, which aid in the digestion of vegetation and in water balance (Clench and Mathias 1995, Kehoe and Ankney 1985).

The colon being the terminal part of the large intestine is located caudal to the ceca. The mean colonic weights and lengths in the quail were $0.82\pm 0.11\text{g}$ and $7.84\pm 0.58\text{cm}$ respectively, while their relative weight and lengths were 6.4% and 8.4% respectively. The pigeon had the weights and lengths of the colon as $0.38\pm 0.04\text{g}$ and $2.22\pm 0.44\text{cm}$ with their corresponding relative weight and length as 2.5% and 2.6% (Tables 1 and 2). The colonic weight in the quail and pigeon were not considered significant statistically but absolutely and relatively they differed from each other. The length of the colon in both bird types were considered significant ($P<0.05$). The findings in this work that the total length of the colon in the pigeon and quail contrasted those reported by Mobini, (2011) who, though worked on a different bird type (broiler) found out that the combined length of colon ranged between 14.64 to 39.84 cm, though as reported by Mobini, (2011) larger birds have relatively longer and heavier intestines than smaller birds. It was also observed that growth rate is a key morphological characteristic which is correlated with robustness in birds and therefore, ascertaining growth rate and developmental stages could provide valuable information on their physiology and behavior (Gebhardt-Henrich et al., 1998; Starck and Ricklefs, 1998).




Plate 1. GIT of the Quail, showing: A=Esophagus, B=Crop, C=Proventriculus, D=Gizzard, E= Small intestine, F= Right cecum, G=Left cecum; H= Colon.

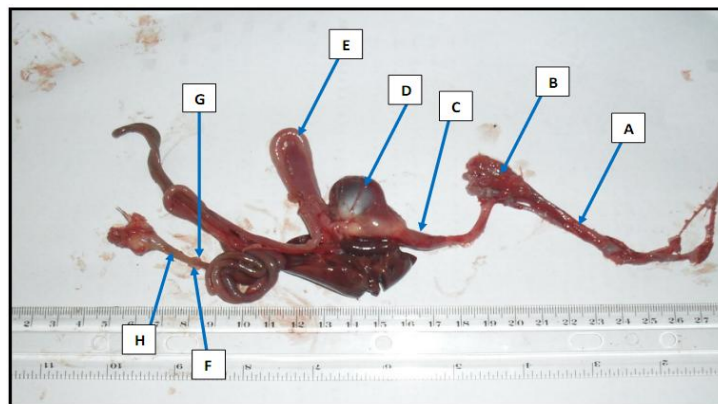


Plate 2. GIT of the Pigeon showing: A=esophagus, B=Crop, C=Proventriculus, D=Gizzard, E= Small intestine, F= Right cecum, G= Left cecum; H=Colon.

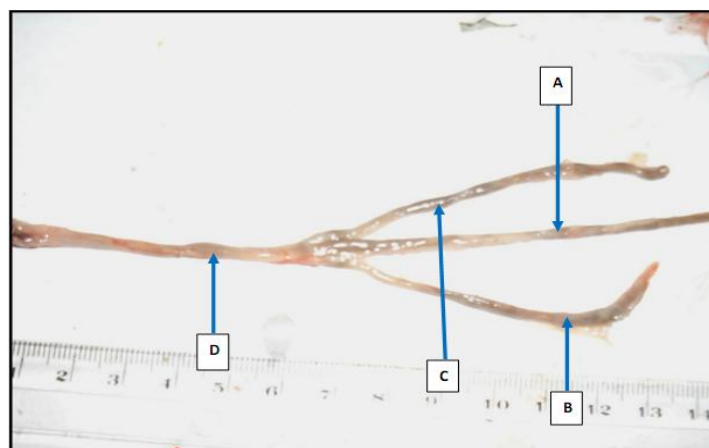

Plate 3. Ceca of the Quail showing: A= Small intestine (Ileum), B= Right cecum, C=Left cecum; D= Colon.




Plate 4. Some segments of GIT of the Pigeon showing: A= small intestine (Ileum), B= Right cecum, C= left cecum; D= Colon.

Table 1

Morphometrical data of some parts of the GIT of Quail (\pm SEM)

Parameter	Weight (g)	Length (cm)	Relative Weight (%)	Relative Length (%)
Esophagus	1.66 \pm 0.15	9.77 \pm 0.35	12.9	10.4
Proventriculus	0.69 \pm 0.07	1.75 \pm 0.13	5.7	1.87
Gizzard	4.06 \pm 0.22	2.38 \pm 0.20	31.6	2.54
Small Intestine	4.56 \pm 0.36	55.6 \pm 2.68	35.5	59.4
Right Cecum	0.53 \pm 0.10	8.13 \pm 0.26	4.1	8.7
Left Cecum	0.53 \pm 0.11	8.13 \pm 0.26	4.1	8.7
Colon	0.82 \pm 0.11	7.84 \pm 0.58	6.4	8.4

Mean body weight =159.5 \pm 8.18 g; n=10.

4. Conclusion

Various anatomical and physiological parameters are regularly being used in clinical evaluations and for assessing dynamics of growth and associated physiological functions for normal and anomalous developments in birds (Druyan et al., 2009). Changes in both gross and microscopic gut anatomy may be important to a bird's ability to maintain energy balance. Seasonal changes in the sizes of digestive organs occur in wild birds, but the proximate factors for such changes are poorly understood, these changes could become very important markers in identifying growth patterns which consequently could be useful tools for predicting both physiological and pathological

consequences (Tilgar et al., 2008). The current study attempted to explain the morphological as well as the morphometrical features of the gastrointestinal tract of the quail and pigeon the knowledge of which will not only add to literatures in these bird types but which will also aid in understanding their biology and mode of domestication as well as being useful for poultry pathologists and clinician, more especially when carrying out postmortem examination. Further studies are recommended to improve the knowledge on the biology of quail and pigeon.

Table 2
Morphometrical data of some parts of the GIT of Pigeon (\pm SEM).

Parameter	Weight (g)	Length (cm)	Relative Weight (%)	Relative Length (%)
Esophagus	1.62 \pm 0.21	12.46 \pm 0.99	10.7	14.7
Proventriculus	0.54 \pm 0.09	1.44 \pm 0.28	3.6	1.7
Gizzard	6.86 \pm 0.69	2.75 \pm 0.25	45.3	3.2
Small Intestine	5.73 \pm 0.04	65.12 \pm 4.02	37.9	76.8
Right cecum	-	0.36 \pm 0.05	-	0.4
Left cecum	-	0.38 \pm 0.06	-	0.4
Colon	0.38 \pm 0.04	2.22 \pm 0.44	2.5	2.6

Mean body weight =265 \pm 4.86 g; n=10.

Table 3
Mean total lengths and weights of the GIT of Quail and Pigeon.

Parameter	Quail (n=10)	Pigeon (n=10)
Total Length of GIT (cm)	93.6	84.73
Total Weight of GIT (g)	12.85	15.13

References

- Ahmed, Y.A.E., Kamel, G., Ahmad, A.A.E., 2011. Histomorphological studies on the stomach of the Japanese quail. *Asian Journal of Poultry science* 5(2):56-67
- Baumgartner, J., 1994. Japanese quail production, breeding and genetics. *World Poul Sci J*, 50: 227-235.
- Brugger, K.E., 1989. Digestive responses to changes in diet, season, photoperiod and temperature in the red-winged blackbird (*Agelaius phoeniceus*). PhD Dissertation, Gainesville Univ., Florida.
- Brugger, K.E., 1991. Anatomical adaptation of the gut to diet in Red-winged blackbirds (*Agelaius phoeniceus*). *The AUK* 108:562-567.
- Casotti, G., 2001. Luminal morphology of the avian lower intestine: Evidence supporting the importance of retrograde peristalsis for water conservation. *Anatomical Record*, 263: 289 – 296.
- Clench, M. H., Mathias, J. R., 1995. The avian cecum-A review. *Wilson Bull.*, 107:93-121.
- Degen, A.A., Duke, G.E., Reynhout, J.K., 1994. Gastrointestinal motility and glandular stomach function in young ostriches. *Auk*, 111:750-755.
- Dibner, J. J., Richards, J. D., 2004. The Digestive System: Challenges and Opportunities. *J. Appl. Poul. Res.*, 13:86–93.
- Druyan, S., Shinder, D., Shlosberg, A., Cahaner, A., Yahav, S., 2009. Physiological parameters in broiler lines divergently selected for the incidence of Ascites. *Poult. Sci.*, 88: 1984-1990.
- Dzialis-Szczepanczyk, E., Wesolowska, I., 2008. Morphometric characteristics of esophagus and intestine in tufted ducks (*Aythya fuligula*) wintering on the baltic coastal areas in north-western Poland. *Electronic Journal of Polish Agricultural Universities*, 11(4), 1 – 35.
- Getty, R., 1975. Sisson and Grossmans. *The anatomy of the domestic animals*, Vol.2. 5th Ed. W.B. Saunders, London, Pp: 1872-1875.
- Gebhardt-Henrich, S.G., Heeb, P., Richner, H., Tripet, F., 1998. Does loss of mass during breeding correlate with reproductive success? A study on Blue Tits *Parus caeruleus*. *Int. J. Avi. Sci.*, 140: 210-213.
- Gibbs, D., Eustace, B., John, C., 2007. *Pigeon and Doves. A Guide to the Pigeons and Doves of the World*. United Kingdom: Pica Press. Pp 624. ISBN 1873403607.

- Igwebuike, U.M., Eze, U.U., 2010. Morphological characteristics of the small intestine of the African pied crow (*Corvus albus*). *Animal Research International* 7(1): 1116 – 1120.
- Johnston, R.F., Janiga, M., 1995. Feral pigeons. Possible Relevance of Pigeons as an Indicator Species for Monitoring Air Pollution. Oxford University Press, New York, New York, USA. p319.
- Kehoe, F.P., Ankney, C.D., 1985. Variation in digestive organ size among five species of diving ducks (*Aythya spp*) *Can. J. Zool.*, 63: 2339-2342.
- Kigir, E.S., Sivachelvan, M.N., Kwari, H.D., Sonfada, M.L., Yahaya, A., Thilza, I.B., Wiam, I.M., 2010. Gross and Microscopic Changes in the Gonads of Male and Female Domestic Pigeon (*Columbia Livia*). *New York Science Journal* 3(10)108-111.
- Lavin, S.R., Karasov, W.H., Ives, A.R., Middleton, K.M., Garland, T., 2008. Morphometrics of the avian small intestine compared with that of non-flying mammals: a phylogenetic approach. *Physiological and Biochemical Zoology* 81: 526 – 550.
- Minvielle, F., 1998. Genetic and breeding of Japanese quail for production around the world. Proc 6th Asian Pacific Poultry Congress, Nogaya, Japan. June, 4-7.
- Mobini, B., 2011. Age dependent morphometric changes of different parts of small and large intestines in the Ross broilers. *IJAVMS* 5(5):456-463.
- Omojola, A.B., Isa, M.A., Jibir, M., Ajewole, B.T., Garba, S., Kassim, O.R., Omotoso, A. B., Adeyemo, O.A., Akinleye, S.B., 2012. Carcass Characteristics and Meat Attributes of Pigeon (*Columbia Livia*) as Influenced by Strain and Sex. *J. Anim. Sci. Adv.*2(5):475-480.
- Parchami, A., Dehkordi, R.A.F., 2011. Histological characteristics of the esophageal wall of the common Quail. *World Applied Sciences Journal* 14(3):414-419.
- Pesek, L., 1999. The Avian digestive tract. In: *Winged wisdom Pet Bird magazine*, Ezine August, 1999.
- Smith, L.S., 1989. Digestive functions in teleost fish. In: *Fish Nutrition (J.E. Halvert, Ed)*. San Diego, Academic Press 331-421.
- Starck, J.M., Ricklefs, R.E., 1998. Variation, constraint and phylogeny. Comparative analysis of variation in growth. In *Avian Growth and Development* (Ed. J.M. Strack and R.E. Ricklefs), pp: 247-265. New York: Oxford University Press.
- Tilgar, V., Kilgas, P., Viitak, A., Reynolds, S.J., 2008. The rate of bone mineralization in birds is directly related to alkaline phosphatase activity. *Physiol. Biochem. Zool.*, 81:106-111.
- Vatsalya, V., Arora, K.L., 2011. Association between body weight growth and selected physiological parameters in male Japanese quail (*Coturnix japonica*). *Int. J. Poult Sci.*, 10: 680-684.
- Wang, J. X., Peng, K. M., 2008. Developmental morphology of the small intestine of African ostrich chicks. *Poultry Science*, 87: 2629 – 2635.